

ORIGINAL ARTICLE

Hepatoprotective Effect of Aqueous Extract of Stem Bark of Berberis Lycium Royale in Isoniazid Induced Hepatotoxicity in Mice

Saima Rafiq¹, Adnan Jehangir², Samina Iltaf³

ABSTRACT

Objective: To determine the hepatoprotective effect of Aqueous extract of Stem Bark of Berberis Lycium Royale in Isoniazid (INH) induced hepatotoxicity in mice.

Study Design: Experimental study.

Place and Duration of Study: The study was conducted from 7th April 2014 till 7th May 2014 at animal house of National Institute of Health, Islamabad.

Materials and Methods: Fifty six male albino Balb/C mice were randomly divided into four groups i.e Group I: Control group (C), Group II: Drug treated group (D), Group III: Low Aqueous group (LA), Group IV: High Aqueous group (HA) of 14 mice each. INH (50 mg/kg) was given to induce hepatotoxicity in all groups except control group (C). Aqueous extract of stem bark of Berberis Lycium Royle was given in low doses (150 mg/kg) to Low Aqueous group (LA) and in high doses (200 mg/kg) to High Aqueous group (HA). Blood samples were collected at day (0, 15th & 30th) for estimation of Liver function tests (LFTs). At the end samples for liver histopathology were taken.

Results: INH produced severe hepatotoxicity as depicted by raised LFT's & severe steatosis, hepatocytic ballooning & inflammation. In animals of Low Aqueous group (LA) and High Aqueous group (HA), serum levels of biomarkers were decreased and their liver sections showed improved histological picture but the reduction in toxic effects were more pronounced in animals treated with high Aqueous group. (HA).

Conclusion: Aqueous extract of stem bark of Berberis Lycium Royale has more significant hepatoprotective potential in high doses as compare to low doses.

Key words: *Steatosis, Liver Function Tests (LFT's), Hepatoprotective, Isoniazid (INH), Berberis Lycium Royale.*

Introduction

Isoniazid (INH) is among one of the most frequently prescribed first line anti-tuberculosis drug.¹ It causes hepatotoxicity in 12% of treated patients and it is limiting its use in these patients.² Drug induced hepatotoxicity (DIH) is mainly caused by three mechanisms i.e direct cell stress, direct mitochondrial impairment, and specific immune reactions.³ INH induced hepatotoxicity is caused by bioactivation of acetylhydrazine, a metabolite of INH.⁴ INH induced hepatotoxicity clinically manifests by raised LFT's and histopathological changes of liver showing steatosis, hepatocytic ballooning and inflammatory changes.⁵⁻⁷ Previous studies have been

done on hepatoprotective effect of aqueous extract of Berberis Lycium Royale in combination with other herbs. No study has been done individually on Berberis Lycium Royale. Our research is designed to evaluate the hepatoprotective effect of aqueous extract of stem bark of Berberis Lycium Royale specifically by measuring LFT's (ALT, AST, ALP & total Bilirubin) and observing histopathological changes of liver. According to medicinal knowledge Berberis Lycium Royle has hepatoprotective properties.⁸ Berberis Lycium Royle is known as Barberry in English, Kashmal in Hindi, Sumbloo in Urdu, Ziarlargay in Pushto.⁹ Stem and the stem bark contain an important component Berberine in a proportion of 4.2%¹⁰ and is known to have the hypoglycemic potential.¹¹ They are used for the cure of jaundice, rheumatism and eye infections. The stem bark is very efficacious in the treatment of ear injury, headache and whooping cough.¹² Berberis Lycium Royle is found to have hepatoprotective effect.¹³

The purpose of present study was to explore the hepatoprotective effects of aqueous extract of stem bark of Berberis Lycium Royle individually on INH

^{1,2}Department of Pharmacology/ Histopathology³

Islamic International Medical College

Riphah International University, Islamabad

Correspondence:

Dr. Saima Rafiq

Department of Pharmacology

Islamic International Medical College

Riphah International University, Islamabad

E-mail: saimarafiqu34@gmail.com

Received: March 31, 2015; Accepted: December 01, 2015

induced hepatotoxicity in mice model.

Materials and Methods

An explorative animal study was carried out in animal house of National Institute of Health (NIH), Islamabad from 7th April 2014 till 7th May 2014. A total of fifty six healthy male albino Balb/C mice, weighing 28-38g and aged between 6-8 weeks, having normal LFT's were included in study. All mice were acclimatized for one week. Then they were randomly divided in four groups (group I-IV), each group containing 14 mice (n=14). Group I (n=14) served as the normal control group (C) given normal diet and fresh water orally. Group II was Drug treated group (D) given INH (50mg/kg body wt)¹⁴ Group III was Low dose Aqueous extract (LA) group received low dose (150 mg/Kg body wt) & Group IV was High dose Aqueous extract (HA) group given high dose (200 mg/Kg body wt) of aqueous extract of stem bark of Berberis Lycium Royle along with INH (50 mg/kg body wt). The herb and the drugs were given orally for four consecutive weeks. Mice were housed under controlled conditions of room temperature $20 \pm 2^\circ\text{C}$, relative humidity 50% - 70% and 12-h light-dark cycle. They were provided free access to water ad libitum. All mice received the care in accordance with the NIH guidelines.

The stem bark of Berberis Lycium Royle was collected from village Prang, Charsadda. It was identified by a botanist Ghulam Jillani at Herbarium section of Botany department, Peshawar University. It was then washed with water thoroughly and shade dried. It was grounded into a fine powder with the help of an electrical grinder and taken into a non-metallic jar. The bark powder was soaked in distilled water for 72 hours with periodic stirring. It was then filtered using Whatmann filter paper no 1. The filtrate was evaporated at 55°C in a rotary evaporator at the research laboratory of Riphah Institute of Pharmaceutical Sciences (RIPS), Islamabad. The extract was obtained as a dark brown semi-solid sticky paste. It was stored in air tight glass bottles, protected from light and kept in refrigerator at $2-8^\circ\text{C}$ to be used throughout the experiment. The yield of aqueous extract of stem bark of Berberis Lycium Royle with respect to the original dry plant material was about 25%.¹⁵ Blood samples of 2 mice from each group were collected at day 0 for baseline LFT's & at day 15th for evaluation of progress of research. Finally

blood samples of 10 mice from each group were taken at day 30th for final evaluation of LFT's. Blood samples of 2 ml were collected in sterile vacutainer with gel by performing cardiac puncture. All blood samples were allowed to clot and serum was separated from the clotted blood samples by centrifugation at 3000 rpm for 10min, using bench top centrifuge machine. All of the serum samples were stored in serum cups at -20°C until used for biochemical evaluation.¹⁶ ALT, AST & ALP were estimated by commercially available kits (Merck pharma) & total bilirubin by (Spectrum Diagnostics kit). Serum ALT, AST, was estimated by IFCC, ALP by Optimised standard method¹⁷ & total bilirubin by Calorimetric method.¹⁸ At the end of experiment liver samples were removed and preserved in 10% formalin after anesthetizing mice. Slides were prepared and stained by using haematoxylin and eosin (H & E stain). Microscopic study of slides was done under 40X objective for steatosis, hepatocytic ballooning and inflammatory infiltrates. Descriptive statistics were applied using one way ANOVA test on SPSS 20. The level of significance was pre-defined as <0.05 ($p < 0.05$).

Results

Effect of Berberis lycium Royale on serum Alanineaminotransferase (ALT) levels

Isoniazid caused significantly increased level of serum ALT (183.1 ± 63.32) in mice of drug treated group (D) as compared to control group C (53 ± 4.99), but these levels were further reduced in mice of (LA) group (78.90 ± 3.85) and more significantly reduced in (HA) group (58.3 ± 3.93) treated with Berberis Lycium Royale. (Table I)

Effect of Berberis Lycium Royale on serum Aspartate aminotransferase (AST) levels

Results showed that level of serum AST was significantly increased ($p < 0.001$) in mice of drug treated group (D) given INH as compared to control group (C), but these levels were greatly reduced in mice of (LA) group and more significantly reduced in (HA) group treated with Berberis Lycium Royale.

Effect of Berberis Lycium Royale on serum Alkaline phosphatase (ALP) levels

Serum ALP level was significantly increased ($p < 0.001$) in mice of Drug treated group (D) given INH as compared to control group (C). ALP levels were reduced in (LA) group with significant reduction in

(HA) group treated with Berberis Lycium Royale. Effect of Berberis Lycium Royale on serum total bilirubin levels. Similar results were observed for

Table I: Comparison Of Liver Function Tests (LFT's) in different Groups

Animal Group No. (n=10)	T.Bil (mg/dl) (0-0.9 mg/dl)	ALT (U/L) (17-77 U/L)	AST(U/L) (54-298 U/L)	ALP(U/L) (35-96 U/L)
Group I (C)	0.10 ± 0.0	53 ± 4.99	107.1 ± 18.46	88.6 ± 1.24
Group II (D)	1.26 ± 0.069	183.1 ± 63.32	428.9 ± 55.32	173.6 ± 28.89
Group III (LA)	0.50 ± 0.226	78.90 ± 3.85	263.5 ± 28.72	99.1 ± 3.93
Group IV (HA)	0.19 ± 0.137	58.3 ± 3.93	117.9 ± 16.97	87.8 ± 1.66
p-value	< 0.001*	< 0.001*	< 0.001*	< 0.001*

*= p – value Significant

(ALT= Alanine aminotransferase,

AST= Aspartate aminotransferase,

ALP =AlkalinePhosphatase, T. Bil=Total Bilirubin)

Table II: Post-hoc comparison of Total bilirubin & ALT between the groups

Group Comparisons	Total Bilirubin		ALT	
	Mean difference	p-value	Mean difference	p-value
Group C vs. Group D	- 1.16	< 0.001*	- 130.1	< 0.001*
Group C vs. Group LA	- 0.40	< 0.001*	- 25.9	0.522
Group C vs. Group HA	- 0.09	0.855	- 5.30	0.999
Group D vs. Group LA	0.76	< 0.001*	104.2	< 0.001*
Group D vs. Group HA	1.07	< 0.001*	124.8	< 0.001*
Group LA vs. Group HA	0.31	0.003*	20.6	0.744

Table III: Post-hoc comparison of AST & ALP between the groups

Group Comparisons	AST		ALP	
	Mean difference	p-value	Mean difference	p-value
Group C vs. Group D	- 321.8	< 0.001*	- 85.0	< 0.001*
Group C vs. Group LA	- 156.4	0.008*	- 10.5	0.993
Group C vs. Group HA	- 10.8	1.000	0.8	1.000
Group D vs. Group LA	165.4	0.004*	74.5	0.002*
Group D vs. Group HA	336.7	< 0.001*	85.8	< 0.001*
Group LA vs. Group HA	171.3	0.003*	11.3	0.990

*= p – value Significant

(ALT= Alanine aminotransferase,

AST= Aspartate aminotransferase,

ALP=AlkalinePhosphatase,

T. Bil=Total Bilirubin)

serum total bilirubin levels showing slight reduction in (LA) group followed by significant reduction ($p < 0.001$) in (HA) group both treated with Berberis Lycium Royale.

Histopathological Examination

Histological examination of H & E preparations of liver specimen of control group (C) showed normal gross appearance i.e. reddish brown color of liver having smooth surfaces, microscopically normal lobular appearance having normal central vein, portal tract and radiating cords of hepatocytes (Fig 1).

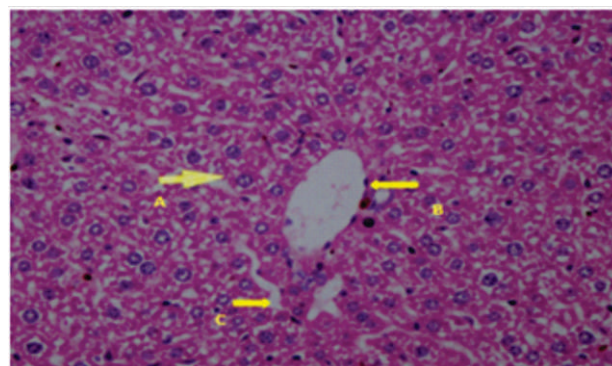


Fig 1: Photomicrograph of the section of Liver of an animal no. 1 of control group C showing [Hepatocyte (A), Central vein (B), Sinusoid space (C)]. H & E Stain, 40 X

Drug treated group (D) mice who were given INH, showed moderate to severe liver damage characterized by severe steatosis, marked hepatocytic ballooning and heavy inflammatory infiltrates (Fig 2).

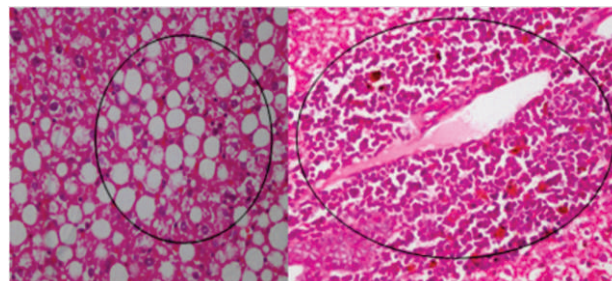


Fig 2: Photomicrograph of section of liver specimen of Drug treated group showing severe steatosis and perivascular inflammatory infiltrate. H & E Stain, 40X

Histological examination of H & E preparations of liver specimen of aqueous extract treated group revealed reversal to mild perivascular inflammation, mild portal inflammation, mild intralobular inflammation, mild steatosis and few ballooned cells in low dose (150mg/Kg) and minimal inflammation, minimal steatosis, minimal hepatocytic ballooning in high doses treated group (200 mg/Kg) (Fig 3).

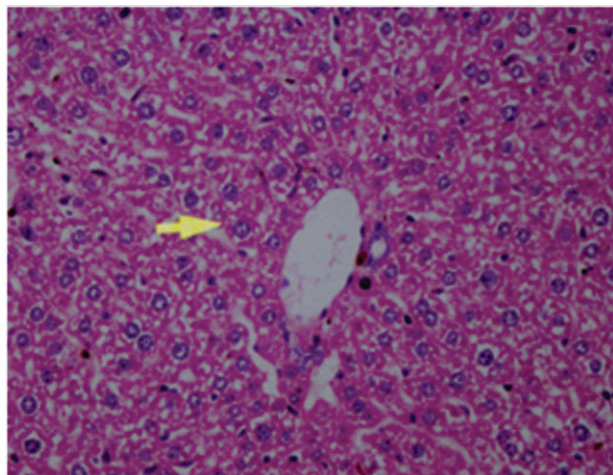


Fig 3: Photomicrograph of section of liver specimen of aqueous extract treated group showing minimal inflammation, minimal steatosis and minimal hepatocytic ballooning

Discussion

Hepatotoxicity is a common side effect when treating TB patients during anti-tuberculosis treatment.¹⁹ Hepatotoxicity due to anti-tubercular drugs is found to be mediated through oxidative stress and free radical damage to hepatocytes.²⁰ It is documented that in sub-acute and chronic inflammation, reactive oxygen species (ROS) play a major role in modulating the degree of inflammatory response and subsequent tissue and cell injury. Antioxidants are well considered as probable protective agents in decreasing the oxidative damage of human body from ROS and impede the progress of many diseases.⁷

Berberis Lycium is found as a best source of free radical scavenging compounds.²¹ Our study was designed to explore the hepatoprotective effect of aqueous extract of Berberis Lycium Royale. Our study results showed that aqueous extract of stem bark of Berberis Lycium Royle has significant hepatoprotective activity ($p < 0.001$) in dose-dependent manner. High dose of extract (200mg/kg body wt) lowered ALT, AST, ALP and total bilirubin (LFTs) level to a greater extent as compared to low dose (150mg/kg body wt). Significant elevation was noticed in levels of serum ALP, AST, ALT, and total bilirubin in group D which were given combination of isoniazid and rifampicin as compared to group C mice which received no medications. Increased levels of (LFTs) are markers of hepatotoxicity. Combined administration of high dose (200mg/kg)

Berberis Lycium Royle aqueous extract with isoniazid and rifampicin in high aqueous (HA) group, restored ALP, AST, ALT, serum total bilirubin towards normal level as compared to drug treated group (D). It was most probably due to anti-oxidant effect of Berberis Lycium Royle. Our research results are in accordance with study carried by Khan & his colleagues in 2011 which showed hepatoprotective activity of aqueous extract of Berberis Lycium Royale in combination with Gallium aparine & Pistacia Integerrima in Ccl4 treated rabbits.¹⁵ Our research results are also found in correlation with another study showing hepatoprotective effect of Berberis Lycium in six poly herbal formulations including Livokin (Herbo-med, Kolkata) in paracetamol induced hepatotoxic mice model²² Studies have been done on combination of Berberis Lycium Royale with other herbs regarding hepatoprotective activity. No study has been done individually on aqueous extract of stem bark of Berberis Lycium Royale regarding hepatoprotective activity. Our research results proved the hepatoprotective effect of aqueous extract of stem bark of Berberis Lycium Royale individually.

No histopathological studies of liver specimens have been done to explore the hepatoprotective role of Berberis Lycium Royle. In our study there was greasy appearance and yellow discoloration of liver specimens in drug treated group (D) given isoniazid. Similar observations were recorded by Imber in 2002 while doing research on hepatic steatosis and its relationship to liver transplantation.²³ Steatosis is the most important histological feature of drug induced liver injury (DILI). In our research moderate to severe steatosis was observed in most of the mice of drug treated group (D) (Figure 22). Similar results were also observed by Hassan in 2012 while inducing hepatotoxicity in rabbit by using isoniazid.⁵ Mice treated with Berberis Lycium Royle showed reverse steatotic changes produced by isoniazid giving evidence of hepatoprotective potential in experimental groups which received extracts of Berberis Lycium Royle. Hepatocytic ballooning is the important marker to distinguish steatohepatitis from simple steatosis. It is the most important characteristic feature of steatohepatitis.²⁴

In our study there was prominent ballooning in many hepatocytes of drug treated group (D) which received isoniazid. Our study results correlate with the

research done by Maryam in 2010 who induced hepatotoxicity in rabbits by isoniazid.⁶ Similar results were also found by Hassan in 2012 while doing research on the effect of *Nigella sativa* (Black seeds) in isoniazid (INH)-induced hepatotoxicity in rabbits.⁵ Our study results showed that aqueous extract of *Berberis Lycium Royale* significantly reversed hepatocytic ballooning with best reversal in high dose aqueous extract treated group as compare to low dose aqueous extract treated group.

Severe inflammation was observed in drug treated group (D) given isoniazid. Drug treated group (D) showed severe inflammation. Our results are in accordance with the study done by Hassan in 2012 while inducing hepatotoxicity in rabbit by using isoniazid.⁵

Our research results indicate that aqueous extract of *Berberis Lycium Royale* significantly reverse inflammatory changes ($p < 0.001$) with more best reversal obtained with high dose (200 mg/Kg body wt) aqueous group (HA).

Histopathological changes induced by isoniazid were improved after giving aqueous extract of *Berberis Lycium Royle*. Hepatoprotective activity may be due to presence of antioxidant properties of flavonoids present in the *Berberis Lycium Royle*.²⁵ No study has been done to find the hepatoprotective effect of aqueous extract of *Berberis Lycium Royle* individually. Our research results proved the hepatoprotective effect of aqueous extracts of stem bark of *Berberis Lycium Royle*.

Conclusion

Aqueous extract of stem bark of *Berberis Lycium Royle* has significant hepatoprotective potential in isoniazid induced hepatotoxicity in male mice model in a dose dependent manner.

REFERENCES

1. Miesel L, Rozwarski DA, Sacchetti JC, Jacobs WR, editors. Mechanisms for isoniazid action and resistance. Genetics and Tuberculosis: Novartis Foundation Symposium 217; 1998: Wiley Online Library.
2. Kumar A. A review on hepatoprotective herbal drugs. IJRPC. 2012; 2: 92-102.
3. Russmann S, Kullak Ublick GA, Grattagliano I. Current concepts of mechanisms in drug-induced hepatotoxicity. Current medicinal chemistry. 2009; 16: 3041.
4. Metushi I, Cai P, Zhu X, Nakagawa T, Uetrecht J. A Fresh Look at the Mechanism of Isoniazid-Induced Hepatotoxicity. Clinical Pharmacology & Therapeutics. 2011; 89: 911-4.
5. Hassan AS, Ahmed JH, Al-Haroon SS. A study of the effect of *Nigella sativa* (Black seeds) in isoniazid (INH)-induced hepatotoxicity in rabbits. Indian journal of pharmacology. 2012; 44: 678.
6. Maryam S, Aziz K, Bhatti ASA, Shahzad AW. Effects of Jetepar (glucometamine, glucodiamine and nicotinamide ascorbate) on Isoniazid Induced Hepatotoxicity in Rabbits. Annals of King Edward Medical University. 2010; 16: 37-42.
7. Tayal V, Kalra BS, Agarwal S, Khurana N, Gupta U. Hepatoprotective effect of tocopherol against isoniazid and rifampicin induced hepatotoxicity in albino rabbits. Indian journal of experimental biology. 2007; 45: 1031.
8. Shabbir A, Shahzad M, Arfat Y, Ali L, Aziz RS, Murtaza G, et al. *Berberis Lycium Royle*: A review of its traditional uses, phytochemistry and pharmacology. African Journal of Pharmacy and Pharmacology. 2012; 6: 2346-53.
9. Murad W, Ahmad A, Gilani SA, Khan MA. Indigenous knowledge and folk use of medicinal plants by the tribal communities of Hazar Nao Forest, Malakand District, North Pakistan. Journal of Medicinal Plants Research. 2011; 5: 1072-86.
10. Agrawal S, Kulkarni G, Sharma V. Antimicrobial and anti-inflammatory activities of bark of four plant species from Indian Origin. 2012.
11. Yin J, Zhang H, Ye J. Traditional Chinese medicine in treatment of metabolic syndrome. Endocrine, metabolic & immune disorders drug targets. 2008; 8: 99.
12. Ahmed E, Arshad M, Ahmad M, Saeed M, Ishaque M. Ethnopharmacological survey of some medicinally important plants of Galliyat Areas of NWFP, Pakistan. Asian Journal of Plant Sciences. 2004; 3: 410-5.
13. Girish C, Koner B, Jayanthi S, Rao K, Rajesh B, Pradhan S. Hepatoprotective activity of six polyherbal formulations in paracetamol induced liver toxicity in mice. Indian Journal of Medical Research. 2009; 129: 569-78.
14. Pal R, Valphei K, Singh K, Rana S. Garlic confers hepatoprotection in isoniazid rifampicin induced hepatic injury. Ind J Gastro. 2003; 1: A100.
15. Khan MA, Khan J, Ullah S, Malik SA, Shafi M. Hepatoprotective Effects Of *Berberis Lycium*, *Galium Aparine* And *Pistacia Integerrima* In Carbon Tetrachloride (Ccl4)-Treated Rats. Journal of Postgraduate Medical Institute (Peshawar-Pakistan). 2011; 22: 92.

16. Akpanabiatu MI UIB, Udosen EO, Udon AE, Rat serum electrolytes, lipid profile and cardiovascular activity on nuclea latifolia leaf extract administration. Indian J Clin Biochem. 2005.
17. YDe. Effects of drugs on clinical laboratory tests: AACC Press Washington; 1995.
18. Tietz NW. Clinical guide to laboratory tests: WB Saunders Co; 1995.
19. Society AT, America IDSo. American Thoracic Society/Centers for Disease Control and Prevention/ Infectious Diseases Society of America: controlling tuberculosis in the United States. American journal of respiratory and critical care medicine. 2005; 172: 1169.
20. Sodhi C, Rana S, Attri S, Mehta S, Yaiphei K, Mehta S. Oxidative-Hepatic Injury of Isoniazid-Rifampicin in Young Rats Subjected to Protein and Energy Malnutrition. Drug and chemical toxicology. 1998; 21: 305-17.
21. Zia ur Rehman Mashwani Mak, Sadia Irum, Mushtaq Ahmad. Antioxidant potential of root bark of Berberis Lycium Royle. from galliyat, western himalaya, pakistan pak j bot 45(si). 2013; 45: 231-4.
22. Girish C, Koner B, Jayanthi S, Rao K, Rajesh B, Pradhan S. Hepatoprotective activity of six polyherbal formulations in paracetamol induced liver toxicity in mice. Indian Journal of Medical Research. 2009; 129: 569-78.
23. Imber CJ, St Peter SD, Handa A, Friend PJ. Hepatic steatosis and its relationship to transplantation. Liver transplantation. 2002; 8: 415-23.
24. Hübscher S. Histological assessment of non-alcoholic fatty liver disease. Histopathology. 2006; 49: 450-65.
25. Ahmed S, Shakeel F. Voltammetric determination of antioxidant character in Berberis Lycium Royle, Zanthoxylum armatum and Morus nigra Linn plants. Pak J Pharm Sci. 2012; 25: 501-7.

.....