

Prevalence of agenesis of palmaris longus and its association with gender, body side, handedness and other anomalies of the forearm in a student population in Ghana.

J.K. Abledu, E.B. Offei

School of Veterinary Medicine, University of Ghana, Legon, Accra, Ghana.

Objective: To determine the prevalence of congenital absence of palmaris longus (PL) muscle and its association with gender, handedness, body side and other neighboring anomalies in a Ghanaian population.

Methodology: The presence of PL was determined in 210 subjects using the standard technique; in subjects with an absent PL, four other tests were done to confirm the absence. All subjects were examined for completeness of the palmar arches (Allen's test) and for the presence of flexor digitorum superficialis (FDS) to the little finger using the standard technique.

Results: The estimated prevalence of agenesis of PL was 3.8% with no significant differences in

terms of gender, body side and handedness ($p>0.05$). However, unilateral absence on the right side was more common in females ($p=0.0302$). None of the subjects with absent PL had a concomitant absence of FDS to the little finger or anomalous superficial palmar arch or both.

Conclusion: The prevalence of congenital absence of PL in this Ghanaian population is much lower than values coated in standard textbooks of surgery, and is independent of gender, body side, handedness and neighbouring anomalies like functional loss of FDS to the little finger and anomalous SPA. (Rawal Med J 2014;39: 203-207).

Keywords: Agenesis, palmaris longus, FDS to the little finger, anomalous SPA.

INTRODUCTION

Palmaris longus (PL) is a slender, superficial flexor muscle of the forearm whose attachments (origin and insertion) are anatomically highly variable¹⁻⁵ and is classified phylogenetically as a degenerating muscle. Its main function is to weakly flex the wrist and tense the palmar aponeurosis, synergized by flexor carpi radialis, flexor carpi ulnaris and flexor digitorum superficialis muscles.^{3,6} It is innervated by the median nerve (C6,C7).

Palmaris longus is one of the most variable anatomical entities in the human body. Some of the variations include classical, double, reversed, central, bifid, multiple headed; and in many cases, the muscle may be completely absent (agenesis), either unilaterally or bilaterally.^{2,4,6} It is functionally negligible and often used as graft tendon in a variety of surgical procedures such as correction of ptosis, management of facial paralysis and lip augmentation.^{2,6}

Congenital agenesis of PL has been studied extensively following the first report of its absence.^{6,7}

The prevalence of agenesis of PL varies in different populations. For instance, it is 4.5% in African Americans, 2.9% in Asians and 13.1-14.9% in Caucasians.⁸ The highest prevalence of agenesis of PL reported in the literature was 63.91% in a Turkish population.⁹

To date, only one report has documented exclusively the prevalence of agenesis of PL in Ghanaian subjects.⁶ Whether the agenesis of PL has a significant association with the gender or handedness of an individual or other anomalies such as functional loss of flexor digitorum superficialis (FDS) to the little finger or anomalous superficial palmar arch (SPA) is a subject of controversy. The aim of this study, therefore, was to determine the prevalence of congenital absence of PL and to verify its association with gender, handedness, body side and other neighbouring anomalies in a Ghanaian population.

METHODOLOGY

This cross study included a random sample of 210 individuals of Ghanaian descent (146 males and 64 females) aged 17-28 years (mean age: 22.7 ± 2.1 years) attending school at Koforidua Polytechnic in Ghana. Students were chosen for the study because of higher tendency to cover various ethnic groups. Participation in the study was voluntary and informed consent was obtained from each participant. The inclusion criteria were as follows: being a Ghanaian and having no history of injury, disease or surgery of the upper limb. Each participant completed a questionnaire (that included age, sex, ethnicity and dominant hand) and was examined for the presence or absence of PL tendon, FDS tendon to the little finger and anomalous SPA for both upper limbs.

Assessment of the presence of PL tendon was initially done by the Standard test (Schaeffer's test): The subject was asked to oppose the thumb to the little finger and then flex the wrist.^{6,7,10} If the tendon was not visualized or palpable, 4 additional tests were done to confirm the absence which included Thompson's test^{7,10}, Mishra's test I^{6,10}, Mishra's test II^{7,10} and Pushpakumar's "two-finger sign" method^{7,10}.

Assessment of FDS tendon to the little finger was done by first, confirming full and free range of motion of the proximal interphalangeal joint (PIPJ) of both fingers. Independent function was defined as the ability to flex the PIPJ of the little finger $>90^\circ$ with the PIPJ of the other fingers extended, while common function was defined as the ability to flex the PIPJ of the little finger $>90^\circ$ only when the ring finger PIPJ was also allowed to flex simultaneously. Absent function was the inability to flex the PIPJ $>90^\circ$ even when flexion of the ring finger PIPJ was allowed.¹⁰

Assessment of the completeness of the palmar arches was done using the Modified Allen's test.¹⁰

The data was analysed using Graphpad Prism Software for Window version 6.0 (Graph Pad Software, San Diego, USA; [www. Graphpad.com](http://www.Graphpad.com)). The association between PL agenesis and body side, gender, FDS to the little finger and anomalous superficial palmer arch was assessed using chi-square or Fisher's exact tests where possible. A

value of $p < 0.05$ was considered statistically significant.

RESULTS.

Out of the 210 subjects, 13 (6.2%) were left-handed and 197 (93.8%) were right-handed. The average age of the males was 22.8 ± 2.1 years and that of the females was 22.6 ± 2.1 years (Table 1). Of the 210 subjects, 208 (99%) had PL tendon in at least one of the forearms while 202 (96.2%) had PL tendon in both hands. Congenital agenesis of PL tendon was observed in 8(3.8%) subjects out of the total population, unilateral agenesis was observed in 2.8% (1.4% on each side) of the cases and bilateral agenesis, in 2 (1%) of the cases (Table 1). Gender differences in terms of agenesis of PL tendon was statistically significant only in the right forearm (male = 4.7%; female = 0%; $p=0.0302$), but not in the left forearm (male = 2.1%; female= 0%; $p=0.5556$), both forearms (male=0.7%; female=1.6%; $p=0.5202$) and the overall agenesis (male=2.7%; female=6.3%; $p=0.2600$). None of these individuals had a concomitant absence of FDS to the little or anomalous superficial palmer arch or both. The results of the Allen's test (Table 1) show that a total of 4(1.9%) individuals had anomalous superficial palmer arch with 3 (1.5%) of the cases presenting the condition unilaterally and 1(0.5%), bilaterally (Table 1). In all of these cases, gender differences in the prevalence of anomalous SPA was statistically insignificant ($p > 0.05$). Of the individuals with anomalous SPA, 2 (1%) and 1 (0.5%) respectively had independent and common functions of FDS bilaterally. There was no statistically significant association between FDS to little finger and anomalous palmer arch. Out of the 210 forearms examined for the presence of FDS to the little finger, 5(2.4%) had functional loss, 106(49.4%) had common function and 99 (47.1%) had independent function (Table 1). These prevalence rates in terms of body side (unilateral or bilateral) and gender was not statistically significant. Prevalence of common function of FDS to little finger in left-handed individuals (61.5%) was significantly ($p=0.0002$) higher than in right-handed individuals (7.6%) (Figure 1A). We did not find any statistically significant association between

independent function (left-handed=15.4%;right-handed=11.2%; $p=0.6566$) or absence of FDS to the little finger (left-handed 7.7%; right-handed=0%; $p=0.0664$) and dominant hand.

Table 1. Characteristics of the study subjects and the prevalence of various anomalies of the forearm stratified by sex and body side.

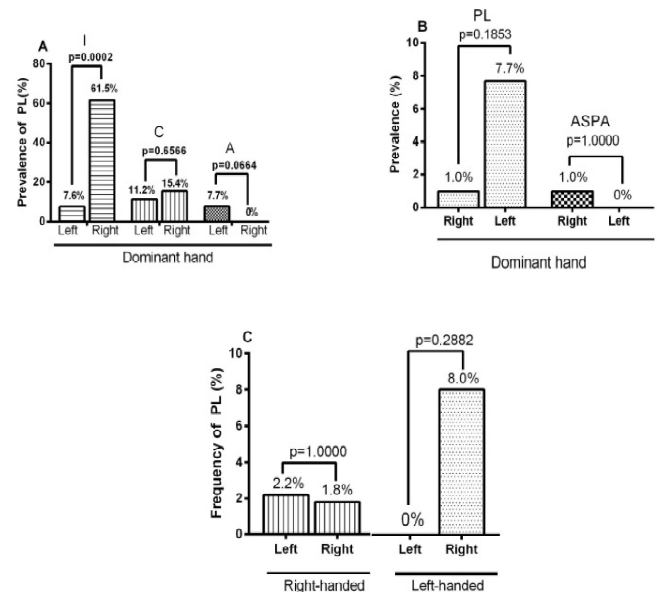
Parameter	Total (n=210)	Male (n=146)	Female (n=64)	P value
Age	22.7±2.1	22.8±2.1	22.6±2.1	0.6136
Dominant hand				
Left	13(6.2)	9(6.2)	4(6.3)	1.0000
Right	197(93.8)	146(93.8)	60(93.8)	1.0000
Absence of PL				
Unilateral left	3(1.4)	3(2.1)	0(0)	0.5556
Unilateral right	3(1.4)	0(0)	3(4.7)	0.0302
Bilateral	2(1.0)	1(0.7)	1(1.6)	0.5202
Overall	8(3.8)	4(2.7)	4(6.3)	0.2600
Positive Allen's test (anomalous SPA)				
Unilateral left	1(0.5)	0(0)	1(1.6)	0.3081
Unilateral right	2(1.0)	2(1.4)	0(0)	1.0000
Bilateral	1(0.5)	1(0.7)	0(0)	1.0000
Overall	4(1.9)	3(2.1)	1(1.6)	1.0000
	Absent	Common	Independent	
FDS to little finger	5(2.4)	106(50.5)	99(47.1)	p value
Unilateral left	1(0.2)	23(18.5)	17(13.9)	0.7257
Unilateral right	0(0)	18(14.5)	23(18.9)	0.4881
Bilateral	4(3.2)	83(68.0)	82(67.2)	0.9665
Male(n=146)	4(2.7)*	83(56.8) [‡]	83(56.8) [‡]	0.9658
Female(n=64)	1(1.6)	41(64.1)	39(60.9)	0.8980

Continuous data is presented as mean ± standard deviation. Categorical data is presented as frequencies and percentages (in parenthesis). * $p=1.0000$; [‡] $p=0.6277$; [‡] $p=0.8062$ when male and female are compared.

In Figure 1B, the prevalence of PL in left-handed individuals (7.7%) was higher than in right-handed individuals (1%) but the difference is not statistically significant ($p=0.1853$). Similarly, the association between dominant hand and anomalous superficial palmar arch did not yield statistically significant results (left-handed=0%; right-handed=1%; $p=1.0000$) (Figure 1B). In both right- and left-handed individuals, the prevalence of agenesis of PL

was higher in the non dominant hand, but this was not statistically significant ($p=1.000$ and $p=0.2882$ respectively) (Figure 1C).

Figure 1 (A) Prevalence of PL agenesis stratified by dominant hand and FSD to the little finger: (1-Independent;C-complete;A-absent). (B) Prevalence of PL agenesis and anomalous superficial palmar arch (ASPA) stratified by dominant hand (C) Prevalence of PL agenesis stratified by dominant hand and body side.



DISCUSSION

Functionally negligible, the palmaris longus muscle has been of morphological interest to Anatomists worldwide. The prevalence of congenital agenesis of PL has been studied extensively with reports varying in different populations. Some authors ^{7,10,11} have also attempted to correlate the agenesis of PL with other anatomical anomalies of the hand. However, most of these studies were carried out in Caucasians and only one report has documented the prevalence of agenesis of this muscle exclusively in Ghanaian subjects. ⁶ To the best of our knowledge, no research has explored the agenesis of PL, functional loss of FDS to the little finger and anomalous SPA as a triadic entity in the

Ghanaian population. The overall (unilateral and bilateral) prevalence of agenesis of PL in this study was 3.8%. This prevalence rate is similar to 3.1% reported by Osonuga, et al.⁶ in the only other study of a Ghanaian population, but differs markedly from 15% (quoted in most Anatomical textbooks) believed to represent Caucasians. The low prevalence of PL agenesis in our study is similar to low prevalence rates of 4.6% in Chinese⁷; 3% and 1.5% in Congolese and Zimbabweans respectively⁶; 1.02% in Ugandans¹² and 6.7% in Nigerians¹³. Interestingly, two studies in Nigeria have reported high prevalence of 12.6%¹⁴ and 31.25%¹⁵ similar to Caucasians; thus reflecting the high ethnic variability of agenesis of this muscle.

There is a seeming controversy in the literature about the symmetry of PL agenesis and whether agenesis is more common in women. There are suggestions that agenesis of PL is more common in females⁶, bilateral agenesis is more common^{12,16} and that unilateral agenesis occurs more frequently on the left.^{6,9} Most of these authors failed to support their conclusions with statistical analysis of the data. The few authors^{7,17,18} who applied statistical analysis did not detect any association between PL agenesis and the side of the body or gender. Our findings compare favorably and we conclude that although unilateral agenesis (2.8%) was more common than bilateral agenesis (1%) and the overall agenesis was more common in females (6.3%) than in males (2.7%) in our population sample, these observations were mainly due to chance. A study reported differential absence of PL with respect to hand dominance and concluded that the PL was more likely to be absent on the non dominant hand.¹⁹ Although our data show a similar trend, it was not statistically significant.

The prevalence of absence of the FDS to the little finger in our study was 2.4%. This value is

comparable to 6.4% reported among Chinese⁷ and 0.25% in Indians¹⁰ but lower than 15%-21% reported in most Caucasian populations²⁰⁻²². In our study, none of the 210 subjects had absolute deficiency of the FDS to the little finger and an absent PL tendon. In the Chinese study, only 1 subject out of a total of 329 had an absolute deficiency of the FDS to the little finger and an absent PL tendon; statistical analysis however, confirmed no correlation between the two. Another study involving 300 patients found only 2 patients with concomitant absence of the PL tendon and FDS to the little finger.²⁰ An Indian study of 400 subjects found only one subject with absence of PL and concomitant absence of FDS to the little finger. Our finding agrees perfectly, and like the previous studies, we conclude that there is no relationship between the functional absence of the FDS to the little finger and the agenesis of PL. Nevertheless, our study also found that the prevalence of common function of FDS to the little finger was more common ($p=0.0002$) in left-handed individuals. A cadaveric study suggested that there was an association between the agenesis of PL and anomalous SPA and out of the 47 cadaveric hands examined, the PL tendon was absent in 25 hands of which 22 had anomalous SPA.¹¹ However, in our study, 4 (1.9%) individuals had anomalous SPA and none of them had an absent PL. This compares favorably with the Indian study. In a related study, only 1 out of the 15 subjects with an absent PL tendon showed a positive Allen's test suggestive of anomalous SPA⁷. We, therefore, believe that there is no association between the agenesis of the PL tendon and anomalous superficial palmar arch.

CONCLUSION

The prevalence of palmaris longus agenesis in the Ghanaian population is lower compared to what is quoted in standard textbooks. Unilateral agenesis

of PL in the right forearm was more common in females. There is no correlation between agenesis of PL and gender, handedness or body side. There seems to be no relationship between the agenesis of PL and neighboring such as functional loss of FDS the little finger and anomalous SPA.

Author Contributions:

Conception and design: JKA, EBO
Collection and assembly of data: JKA, EBO
Analysis and interpretation of the data: JKA, EBO
Drafting of the article: JKA
Critical revision of the article for important intellectual content: JKA, EBO
Statistical expertise: JKA, EBO
Final approval and guarantor of the article: JKA, EBO
Corresponding author email: jkabledu@gmail.com
Conflict of Interest: None declared
Rec. Date: Dec 10, 2013 Accept Date: Jan 29, 2014

REFERENCES

- Fazan, V.P.S. Reversed palmaris longus muscle and median nerve relationships. Case report and literature review. *Braz. J. Morphol. Sci* 24, 88-91 (2007).
- Albay, S., Kastamoni, Y., Sakalli, B. & Tunali, S. Anatomy and variations of palmaris longus in fetuses. *Rom J Morphol Embryol* 54, 85-89 (2013).
- Roohi, S., et al. A study on the absence of palmaris longus in a multiracial population. *Malays Orthop J* 1, 26-28 (2007).
- Morais, M.A., Gomes, M.S., Helrigle, C. & Malysz, T. Prevalence of agenesis of the palmaris longus muscle in Brazil and its clinics correlation. *J. Morphol. Sci* 29, 238-242 (2012).
- Gray, H., Williams, P. & Bannister, L. Gray's Anatomy: The Anatomical Basis of Medicine and Surgery. Churchill-Livingstone. New York, 853 (1999).
- Osonuga, A., et al. The Prevalence of Palmaris longus agenesis among the Ghanaian population. *Asian Pacific Journal of Tropical Disease* 2, S887-S889 (2012).
- Sebastin, S.J., Lim, A.Y. & Wong, H. Clinical assessment of absence of the palmaris longus and its association with other anatomical anomalies-a Chinese population study. *Annals-academy of Medicine Singapore* 35, 249 (2006).
- Soltani, A.M., et al. The Variation in the Absence of the Palmaris Longus in a Multiethnic Population of the United States: An Epidemiological Study. *Plastic Surgery International* Article ID 282959, 4 pages (2012).
- Ceyhan, O. & Mavt, A. Distribution of agenesis of palmaris longus muscle in 12 to 18 years old age groups. *Indian journal of medical sciences* 51, 156 (1997).
- Sharma, D., Shukla, C. & Sharma, V. Clinical assessment of absence of Palmaris longus muscle and its association with gender, body sides, handedness and other neighboring anomalies in a population of central india. *Journal of The Anatomical Society of India* 61, 13-20 (2012).
- O'sullivan, E. & Mitchell, B.S. Association of the absence of palmaris longus tendon with an anomalous superficial palmar arch in the human hand. *Journal of Anatomy* 201, 405-408 (2002).
- Igbigbi, P. & Ssekitoleko, H. Incidence of agenesis of the palmaris longus muscle in Ugandans. *West African J Anat* 6, 21-23 (1998).
- Mbaka, G.O. & Ejiwunmi, A.B. Prevalence of palmaris longus absence—a study in the Yoruba population. *The Ulster medical journal* 78, 90 (2009).
- Enye, L., Saalu, L. & Osinubi, A. The prevalence of agenesis of Palmaris longus muscle amongst students in two Lagos-Based Medical schools. *Int. J. Morphol* 28, 849-854 (2010).
- Oluyemi Kayode, A., Adesanya Olamide, A., Odion Blessing, I. & Ukwenya Victor, O. Incidence of palmaris longus muscle absence in Nigerian population. *International Journal of Morphology* 26, 305-308 (2008).
- Vanderhooft, E. The frequency of and relationship between the palmaris longus and plantaris tendons. *American journal of orthopedics (Belle Mead, NJ)* 25, 38 (1996).
- Alves, N., et al. Study of frequency of the palmaris longus muscle in Chilean subjects. *Int. J. Morphol* 29, 485-489 (2011).
- Thompson, N., Mockford, B. & Cran, G. Absence of the palmaris longus muscle: a population study. *The Ulster medical journal* 70, 22 (2001).
- Eri, M., Krivokoc a, S., Leksan, I. & Vucinic, N. Prevalence of the palmaris longus through clinical evaluation. *Surgical and Radiological Anatomy* 32, 357-361 (2010).
- Thompson, N., Mockford, B., Rasheed, T. & Herbert, K. Functional Absence of Flexor Digitorum Superficialis to the Little Finger and Absence of Palmaris Longus—Is There A Link? *The Journal of Hand Surgery: British & European Volume* 27, 433-434 (2002).
- Baker, D.S., Gaul Jr, J.S., Williams, V.K. & Graves, M. The little finger superficialis—clinical investigation of its anatomic and functional shortcomings. *The Journal of hand surgery* 6, 374-378 (1981).
- Austin, G.J., Leslie, B.M. & Ruby, L.K. Variations of the flexor digitorum superficialis of the small finger. *The Journal of Hand Surgery* 14, 262-267 (1989).