

Research Article

The Role of B-Lines on Transthoracic Ultrasonography in Patients of Interstitial Lung Disease

Afshan Qureshi¹, Salman Ayyaz², Asif Hanif³, Yasir Nasir⁴, Muhammad Saqib Saeed⁵

¹Assistant Professor of Chest Radiology, Institute of TB & Chest Medicine, KEMU/ Mayo Hospital Lahore; ²Associate Professor, Institute of TB & Chest Medicine, KEMU/ Mayo Hospital Lahore; ³Assistant Professor, Institute of TB & Chest Medicine, KEMU/ Mayo Hospital Lahore; ⁴Senior Registrar, Institute of TB & Chest Medicine, Mayo Hospital Lahore; ⁵Chairman, Institute of TB & Chest Medicine, KEMU/ Mayo Hospital Lahore

Abstract

Background: Gold standard for the diagnosis is High Resolution Computed Tomography (HRCT). It provides all detailed morphological depiction of a minimal interstitial lung involvement. However exposure to radiation, high cost and non-availability are its few limitation. Ultrasound chest can play a complimentary part in the disease evaluation.

Objective: To determine the role of B lines on transthoracic ultrasonography in patients of known interstitial lung disease.

Methods: This study was carried out in Institute of TB & Chest Medicine, Mayo Hospital / KEMU Lahore and it continued over a period of six months. About 50 patients of mean age of 50 + 15 years (27 female and 23 males) with known Interstitial Lung Disease (ILD) underwent chest ultrasound for assessment of presence of B-lines and distance between them was measured. These findings compared with that of HRCT findings Ground Glass Opacity (GGO), reticular pattern involving sub pleural region, nodules, honey combing etc).

Results: All patients had bilateral B-lines as they were all diagnosed cases of ILD, the distance between two adjoining lines correlated well with their disease process shown on HRCT where B3 correlated with GGO and B7 correlated with pulmonary fibrosis and honey combing. Study had 22 Non Specific Interstitial Pneumonitis (NSIP) patients, 14 of Idiopathic Pulmonary Fibrosis (IPF), 5 of Sarcoidosis, 4 of Hypersensitivity pneumonitis, 4 of Connective tissue disorder and 1 of Cryptogenic Organizing Pneumonia (COP).

Conclusion: B-lines that are lung ultrasound sign of extensive interstitial pathology seem to be useful in the assessment of ILD as significant correlation was found between lines on ultrasound and HRCT findings.

Corresponding Author | Dr. Afshan Qureshi, Assistant Professor of Chest Radiology, Institute of TB & Chest Medicine, KEMU/ Mayo Hospital Lahore. **Email:** drafshanqureshi@hotmail.com

Keywords | B-lines, Interstitial lung disease (ILD), HRCT, Ground glass opacity.

Introduction

Interstitial Lung Disease (ILD) refer to a group of disorders that are characterized by varying combinations of inflammatory process and fibrosis which involves the space between epithelial and endothelial basement membranes, perivascular and perilymphatic tissues. These have different etiologies, clinical presentations, radiological features and histopathological appearances with

significant morbidity and mortality. Mostly the cause of ILD is not known and it belongs to a idiopathic group or it can be caused by long term exposure to organic or some inorganic materials. Autoimmune diseases like rheumatoid arthritis and diseases like sarcoidosis, cryptogenic organizing pneumonia, drugs, infections and radiation therapy can also cause ILD.

High Resolution Computed Tomography (HRCT) is

the reference technique for the diagnosis of ILD.¹ However exposure to radiation, high cost and non-availability are its limitation especially in monitoring disease progression and serial follow ups. Ultrasound chest can play an important part in the disease evaluation particularly in primary and secondary health care. It is highly sensitive to variations of pulmonary content and balance between fluid and the air.^{2,3,4}

Because of acoustic mismatch between chest wall and adjacent aerated lung there is almost total reflection of ultrasound beam therefore it is not an ideal imaging modality for air filled organs. That's why chest sonography is limited for assessing superficial pulmonary, pleural based pathology abutting the chest wall.⁵

In the last few years B lines have been acknowledged as the transthoracic Ultrasound marker of Interstitial disease process. B-lines are the distinct hyper echoic longitudinal comet-tail artifacts which originates from the pleural line and travel down till the lowest part of screen.. They are seen when air content in the lung is decreased and there is increase in either inflammation, fibrosis or fluid in the interstitium.⁶ The ultrasound estimation of ILD is determined by the presence and number of B-lines which are formed by the degree of reflection of sound waves from thickened interlobular septa in the subpleural region at lung surface interface. Ultrasound technique consist of screening eight regions, four regions on the both sides.

Region 1 and 2 are the upper above nipple and lower below nipple regions anteriorly and 3 and 4 indicate the upper lateral and lower lateral chest regions^(7,8). B-lines are best seen under real time imaging and appear less pronounced on frozen images. Upto 3 B lines are normal in each region. A positive examination is the one when there are greater than 3 lines when the transducer is placed in a longitudinal axis between two adjacent ribs. Such finding in two or more regions is pathognomonic.^{9,10,11}

Transthoracic Ultrasound has many advantages over HRCT, it is non-invasive, non-ionizing, requires no contrast medium, widely available, inexpensive and is readily accepted by the patients. It monitors the progression of disease in patients instead of having

repeated HRCTs for follow up and thus avoiding unnecessary overload of radiation exposure.^{12,13} Previous studies have shown B lines on chest ultrasound can play a complimentary role in the diagnosis and progression of ILD when HRCT is either not available. This can be of great help for the clinicians to assess the critically ill patients unable to mobilize to radiology department. And also can be useful in monitoring course of disease in patients of confirmed ILD.^{14,15}

HRCT is the gold standard technique for ILD diagnosis and interpretation along with many other imaging procedures.^{16,17} HRCT pattern in ILD may show subpleural involvement like subpleural reticulation, thickening of interlobular septa and thickening of intralobular septa with honey combing, ground glass opacity which may be focal or diffuse, nodules (random, centrilobular, perilymphatic distribution), mosaic attenuation, crazy paving pattern, traction bronchiectasis and also additional findings like mediastinal lymphadenopathy, consolidation, pleural effusion and pulmonary hypertension.^{18,19,20}

Methods

It was a cross-sectional study. It continued over a period of 6 months from 1st March to 31st August 2018 and comprised of 50 patients. Inclusion criteria included diagnosed cases of ILD of either gender, no age limit of patients with typical HRCT findings of disease and all patients were on treatment.

Exclusion criteria included patients with pulmonary malignancy, congestive heart failure, Chronic Obstructive Pulmonary Disease (COPD), kyphoscoliosis and critically ill patients with compromised saturation. Study was conducted in Institute of TB & Chest Medicine Department Mayo Hospital / KEMU Lahore. Convenience, non-probability sampling were done. Only cases which fulfilled our criteria were collected from both indoor and outdoor of TB & Chest Medicine Dept. Mayo Hospital /KEMU Lahore. Patients with radiological features highly suggestive of ILD on HRCT were selected. Informed written consent was obtained and their demographics were recorded. Forced Vital Capacity (FVC) and (FEV1) Forced Expiratory volume in 1st sec were measured with computerized lung analyzer in our Department. Ultrasound Chest was performed both

with convex (low frequency) and linear (high frequency) probes to evaluate parenchymal involvement and presence, no of B lines and distance between them were recorded. The distance between each of the two adjoining lines correlated well with the disease process on HRCT where B3 (Distance of 3mm between lines) correlated with ground glass opacity and B7 (Distance of 7mm) correlated with fibrosis and honey combing. It was then compared with HRCT findings (Ground glass, interlobular or intralobular septal thickening, reticulonodular pattern, sub pleural reticulation, honey combing etc. The data was entered in SPSS Version 26. Results were expressed as mean \pm standard deviation or number and percentage. The correlation between different parameters was performed using the Pearson test. The difference was considered significant when $P < 0.05$. Graphics were performed using Microsoft excel.

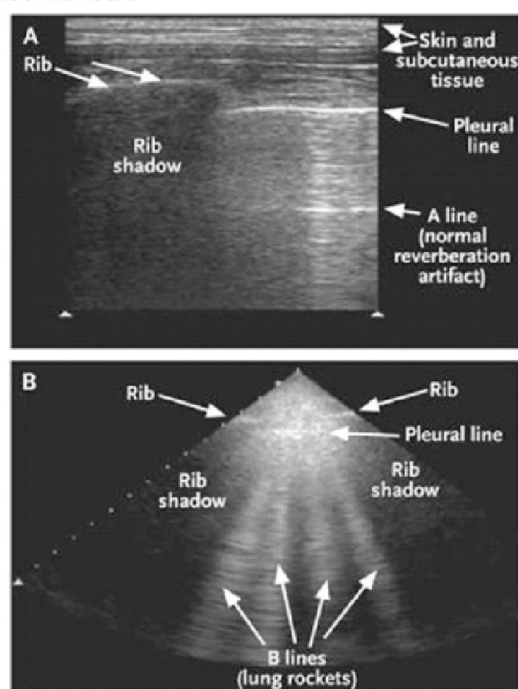


Figure 1: Classic B-lines in Comparison with the Normal Lung Image

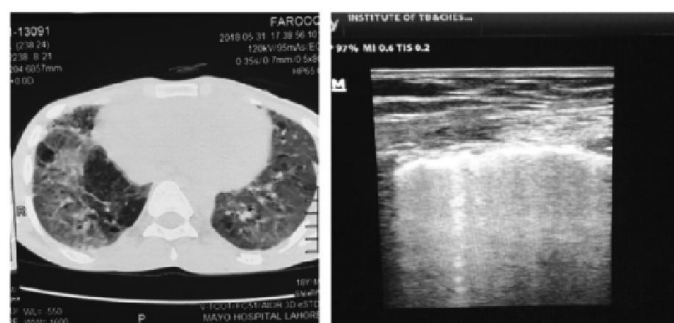


Figure 2: GGO on HRCT and Pleural Thickening

with Diffuse B-lines (B3) on Ultrasound Image

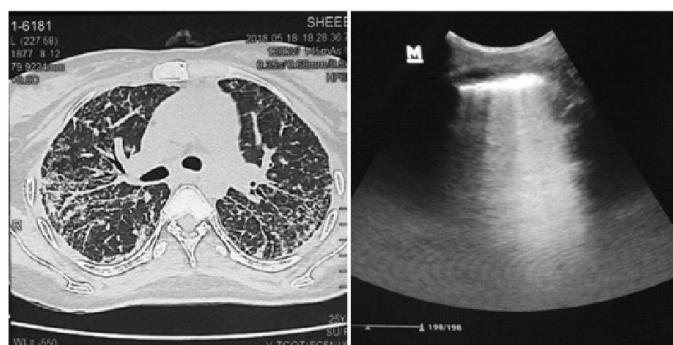


Figure 3: Subpleural Reticulation and Honeycombing on HRCT and Pleural Thickening with Diffuse B-lines (B7) on Chest Ultrasound

Results

Study comprised of 50 patients of mean age of 50+15 years with 27 female and 23 males. Diagnosis of cases was based on clinical features, serological tests, PFT's (spirometry), HRCT findings and transthoracic USG findings. Nearly all patients had dry cough and dyspnea both on rest and exercise. Saturation (SPO2) of between 88%-96% with postexertional drop of more than 6%. Most of the patients had early cor pulmonale.

Spirometry showed mild, moderate to severe restrictive pattern with FEV1 /FVC ratio of more than 70 %. On HRCT chest ground glass opacity was seen in 16% of patients, subpleural reticulation 14%, honey combing 10%, reticulonodular pattern 6% and nodules in 4 % of patients. Ultrasound chest showed all patients had bilateral B lines but more than 3 in the region is pathognomonic. In GGO distance between two adjacent B Lines was narrow (B3) and B lines were numerous giving appearance of white lung. Figure 2 showing GGO on HRCT and diffuse B-lines (B3) on Ultrasound image. In reticulonodular pattern and honey combing the distance between B-lines was wide (B7). Figure 3 showing subpleural reticulation and honeycombing on HRCT and diffuse B-lines (B7) on chest ultrasound. Study had 22 patients of Non specific interstitial pneumonitis (10 males & 12 females). 14 of Idiopathic pulmonary fibrosis (8 males & 6 females), 5 of Sarcoidosis (1 male & 4 females), 4 patients of Hypersensitivity pneumonitis (2 males & 2 females), 4 of Connective tissue disorder (1 male & 3 females) and 1 of Cryptogenic Organizing pneumonia (1 male). Significant

association was seen between B lines on Chest USG and findings on HRCT as the distance between two adjoining lines was suggestive of a particular disease pattern on HRCT. Therefore Lung ultrasound can be a very beneficial modality for the long term follow up of ILD patients after initial examination with HRCT as B Lines may be used as a biomarker to show

Table : Gender Distribution Among Various Types of ILD

Type of Interstitial Lung Disease	Number of Patients	
Non Specific Interstitial Pneumonitis	22	(10 Male, 12 Female)
Idiopathic Pulmonary Fibrosis	14	(8 Male, 6 Female)
Sarcoidosis	5	(1 Male, 4 Female)
Hypersensitivity Pneumonitis	4	(2 Male, 2 Female)
Connective Tissue Disease	4	(1 Male, 3 Female)
Cryptogenic Organizing Pneumonia	1	(1 Male)

fibrosis and also correlate with the severity.

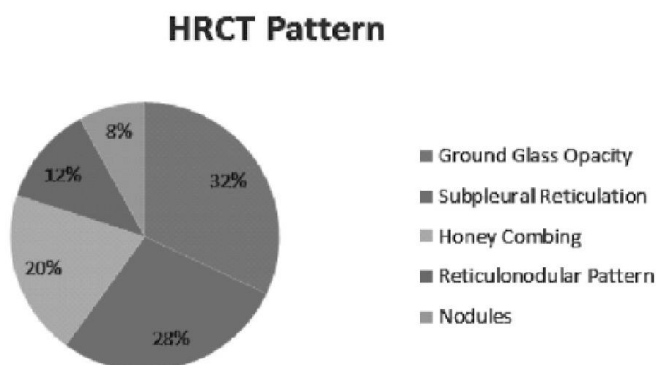


Figure 4: High Resolution Computed Tomography Pattern

Discussion

Bilateral B lines and distance between adjoining lines on chest ultrasound in combination with a thickened, irregular pleura is strongly suggestive of ILD, this has been reported in several other studies.^{2,4,6,8,9} In our study definite association was found between B lines on ultrasound with HRCT findings and Sensitivity for chest ultrasound was found to be 99%, Specificity of 84%, Positive Predictive Value of 90% and Negative Predictive Value of 99% respectively. Our results are comparable to some other international and local studies. Tardella et al reported significant linear correlation between number of B lines and HRCT score ($p < 0.001$)² In the study done by Tatiana Barskova the Sensitivity and Negative predictive

value of 100% was found in Systemic Sclerosis. Tatiana showed that chest ultrasound is very sensitive for detecting ILD even in very early Systemic Sclerosis patients and found that 51% of systemic sclerosis patients had B lines as a hallmark of interstitial pulmonary fibrosis.³ Buda et al correlated both Lung Ultrasound (LUS) findings with HRCT findings and reported many B lines with a white lung appearance consistent with the ground glass opacity ($p < 0.001$) with Sensitivity and Specificity of 95% and 99% respectively.⁴ The reticular pattern on HRCT showed a highly positive correlation with B-line distance and a negative correlation between ground-glass opacity and B-line distance. This was in agreement with the findings of Hasan AA, et al who found that the distance between two B lines positively correlated with the degree of interstitial affection on using the Warick scoring system on HRCT. He showed ground glass pattern in 14 patients (23%), reticular pattern in 20 patients (32.8%), reticulonodular pattern in 12 patients (19.7%), nodular pattern in 2 patients (3.3%) and honey combining in 13 patients (21.2%).⁶ Sayed SS, et al showed subpleural parenchymal lesions on chest ultrasound and these reflected diffuse fibrosing interstitial process and correlating with HRCT findings. He had 12 cases of IPF, 10 cases of HP, 8 of NSIP, 5 of Sarcoidosis and 7 of Lymphangitis carcinomatosa in his study.⁹ Bouhemad et al. found that B-lines 7 mm apart are caused by thickened interlobular septa suggestive of interstitial edema, while B-lines 3 mm or less apart are caused by ground glass opacity indicative of alveolar edema.²¹ However additional studies with higher number of patients are needed to verify the results and to provide more information on the feasibility of B lines on transthoracic ultrasonography in the evaluation of ILD.

Transthoracic ultrasound has many advantages over HRCT, it is a readily available, suitable for bedside use and easily performed examination. In critically ill patients, portable machines can be sufficient for a complete and detailed lung assessment. Finally, ultrasound is useful in situations where HRCT is not available or undesirable, as in pre-hospital emergencies and in pregnancy.^{13,21}

Conclusion

Significant association was seen between presence

of B lines on chest ultrasound and findings on HRCT of ILD patients. Ultrasound is cost effective, non invasive diagnostic modality that require neither ionizing radiations nor contrast medium, therefore these advantages render it a complementary method for the evaluation of ILD patients.

Ethical Approval: Given

Conflict of Interest: The authors declare no conflict of interest

Funding Source: None

References

1. Elicker BM, Kallianos KG, Henry TS. The role of high resolution computed tomography in the follow up of diffuse lung disease : Number 2 in the Series “ Radiology” Edited by Nicola Sverzellati and Sujal Desai . European Respiratory Review. 2017; 26 (144): 170008.
2. Tardella M, Di Carlo M, Carotti M, Filippucci E, Grassi W, Salaffi F, et al. Ultrasound B lines in the evaluation of interstitial lung disease in patients with systemic sclerosis: Cut-off point definition for the presence of significant pulmonary fibrosis. *Medicine*. 2018; 97(18): e0566.
3. Barskova T, Gargani L, Guiducci S, Radone SB, Bruni C, Carnesecchi G, et al. Lung ultrasound for screening of interstitial lung disease in very early Systemic Sclerosis . *Ann Reum Dis*. 2013 ; 72 (3): 390-5.
4. Buda N, Piskunowicz M, Porzezinska M, Kosiak W, Zdrojewski Z. Lung ultrasonography in the evaluation of interstitial lung disease in systemic connective tissue diseases. *Ultraschall Med* . 2016; 37: 379-85.
5. Piette E, Daoust R, Denault A, Basic concepts in the use of thoracic and lung ultrasound . *Curr Opin Anesthesiol* . 2013 ; 26 : 20 – 30 .
6. Hasan AA, Makhoul HA . B-lines Transthoracic ultrasound sign useful in assessment of Interstitial lung disease. *Annals of Thoracic Medicine* . 2014; 9: 99-103
7. Volpicelli G, Elbarbary M, Lichtenstein DA, Blaivas M, Mathis G, Kirkpatrick AW, et al. International Liaison Committee on lung ultrasound for international Consensus Conference on Lung ultrasound. Int. evidence –based recommendations for point of care lung ultrasound. *Intensive Care Med*. 2012; 38: 577-91.
8. Wang Y, Gargani L, Cerinic MM. Usefulness of lung ultrasound B-lines in Connective tissue disease associated Interstitial lung diseases: A literature review . 2017; 19 (1): 206.
9. Sayed SS, Agmy GM, Said AF, Kasem AH. Assessment of transthoracic sonography in patients with Interstitial lung disease. *Egypt J Bronchol*. 2016; 10 (2): 105-112.
10. Lichtenstein DA, Meziere GA, Lagoueyte JF, Biderman P, Goldstein I, Agnes G. A lines and B lines: Lung ultrasound as a bedside tool for predicting pulmonary artery occlusion pressure in the critically ill. *Chest*. 2009 ; 136(4) : 1014-1020..
11. Kreuter M, Herth FJ, Wacker M, Leidl R, Hellmann A, Pfeifer M, et al. Exploring Clinical and Epidemiological Characteristics of Interstitial lung diseases. Rationale, Aims and Design of a Nationwide Prospective Registry _ The EXCITING-ILD Registry. *Bio Med research international*. 2015 ; 2015.
12. Simon LF, Walsh, Devaraj A, Enghelmayer JI, Kishi K, Silva RS, et al. Role of imaging in progressive–fibrosing interstitial lung diseases. *European Respiratory Review*. 2018; DOI: 10.1183/16000617.0073-2018.
13. Volpicelli G. Lung sonography. *J Ultrasound Med*. 2013 ; 32 : 165 – 71.
14. Zubairi ABS, Hassan M, Sarwar S, Abbass A, Ahmad H, Irfan M, et al. Spectrum of interstitial lung disease from tertiary care hospital in Karachi . *JPMA (Journal of the Pakistan Medical Association)* 2017 ; 67 (7) : 1065 -1069.
15. Man MA, Dantes E, Hancu BD, Bondor CI, Ruscovan A, Parau A, et al. Correlation between Transthoracic lung USG score and HRCT features in patients with ILD Diseases. *Journal of Clinical Medicine* . 2019 ; 8 (8) : 1199
16. Ansarie M, A national guideline and ILD PAK Registry Report: Recent landmarks in the understanding of interstitial lung diseases in Pakistan. *JPMA*. 2016; 66(9)
17. Akhter N, Rizvi N. Interstitial lung diseases Misdiagnosed as Tuberculosis . *Pakistan Journal of Medical Sciences*. 2018; 34(2) : 338 – 341.
18. Olson AL, Gilford AH, Inase N, Perez ERF, Suda T. The epidemiology of idiopathic pulmonary fibrosis and interstitial lung diseases at risk of a progressive – fibrosing phenotype. *European Respiratory Review*. 2018 ; 27 : 180077
19. Manolescu D, Davidescu L, Traila D, Oancea C, Tudorache V. The reliability of lung ultrasound in assessment of idiopathic pulmonary fibrosis. *Clin Interv Aging*. 2018 ; 13 : 437-449.
20. Riaz R, Frequency of positive findings on Chest Xray of patients proved to have IPF on High Resolution Computed Tomography (HRCT) . *PJR (Pakistan Journal of Radiology)*. 2016; 26 (3) : 168 173 .
21. Bouhemad B, Zhang M, Lu Q, Rouby JJ. Clinical review: Bedside lung ultrasound in critical care practice. *Crit Care* 2007; 11: 205..222,