

Research Article

Effect of Production of Multiple Keloids on Health of the Animal

Abdul Mannan Babar¹, Abdul Hannan Nagi²

¹Head of the Department of Surgery, Postgraduate Medical Institute, Ameeruddin Medical College, Lahore General Hospital Lahore, Pakistan. ²MBBS, FCPS, FRCP, FRCPath, PhD, Head of the Department of Pathology, Incharge Experimental Research Laboratory, University of Health Sciences, Lahore, Pakistan

Abstract

Keloids are fibrous tumors developed in the process of wound healing. Keloids are found solely in human species, and not in animals. Keloid animal model has been developed by the authors. Now authors want to investigate if multiple keloids can be produced in one animal without causing any untoward effects on the health of that animal.

Objective: To find out effect of production of multiple keloids on health of the animal.

Methodology: the study was Quasi-experimental trial and settings were Experimental Research/Pathology Laboratories, University of Health Sciences, Lahore. The duration was 12 months. Two rabbits were taken; one as control, and other as interventional. In interventional rabbit eight keloids were produced, four on each ear, using Mannan & Hannan technique.

Results: Eight keloids were produced in one animal without causing any untoward effects on the health of that animal.

Conclusion: Multiple keloids can be produced in one animal without causing any untoward effects on the health of that animal.

Received | 10-03-2017: **Accepted** | 20-08-2018

Corresponding Author | Prof. Abdul Mannan Babar, Head of the Department of Surgery, Postgraduate Medical Institute, Ameeruddin Medical College, Lahore General Hospital Lahore, Pakistan

Email: ambabar@gmail.com

Keywords | Cicatrix, Hypertrophic; Keloid; Models, Animal; Rabbit; Transforming Growth Factor beta 1.

Introduction

Keloids are fibrous tumors developed in the process of wound healing. Keloids are in fact benign tumors of dermis of skin. Hypertrophic scars are of somewhat similar pathology, but they do not erode to adjacent structures^{1,2}. Keloids form as a consequence of trauma. They may occur directly after trauma, or may be deferred for a long time. Keloids are of different sizes, and minor injuries can lead to big keloids in some people^{3,4}. True cause of occurrence of this disease is not recognized until now. As such, some causes are supposed to be probable explanations. These factors may be inside or outside

the human beings^{5,6}.

Keloids are found solely in human species, and not in animals. This is the principal obstacle against planned inquiry concerning keloids, as research on human beings is not feasible, and not appropriate. Studies on keloids have routinely been performed on patients, with low level of scientific evidence. No practicable animal model of this condition has been produced so far. The authors have invented a new technique of production of rabbit ear keloid model, called Mannan and Hannan Technique, in which a pro-fibrotic growth factor, called Transforming Growth Factor Beta 1 is used⁷⁻⁹.

Transforming Growth Factor Beta 1 plays an important role in healing of wounds and formation of normal and abnormal scars; it is a potent chemotactic agent for fibroblasts, and stimulates them to manufacture most important extracellular matrix components like collagen. Transforming Growth Factor Beta 1 itself is manufactured by macrophages, and also by extracellular matrix, thereby producing a vicious cycle. Transforming Growth Factor Beta 1 produces its effect by stimulation of fibroblasts, thereby causing increased collagen assembly. Transforming Growth Factor Beta 1 itself is manufactured in larger quantities in keloids, and keloid fibroblasts react in response to lower levels of Transforming Growth Factor Beta 1 than normal skin fibroblasts. Addition of extraneous Transforming Growth Factor Beta 1 activates fibroblasts, thus escalating fabrication of collagen, and development of keloids¹⁰⁻¹³.

Use of animals in experimental studies is a major concern with most of the research institutions all over the world. This involves many ethical problems, and need of humane animal research cannot be underestimated. Improving animal welfare is on international agenda for last half a century. Regarding this, 3R (Replacement, Reduction and Refinement) principles of laboratory animal research were developed by Russell & Burch in 1959¹⁴, and are now gold standard all over the world. Further, animal husbandry is time-, manpower-, and finance-intensive, and consumes bulk of resources of experimental research laboratories. For research involving internal systems of an organism, whole animal is required. But when research involves only local tissue of an animal, especially skin, multiple lesions can be studied in one animal. In this way one animal can act as multiple subjects^{15,16}.

Previously, most of the animal studies have produced one hypertrophic scar/keloid per animal. This has been due to fears about morbidity and mortality of the animals. Diao et al., in 2013 produced four hypertrophic scars on each ear of rabbit¹⁷. Xiao and Xi in 2013 produced three hypertrophic scars on each ear of rabbit¹⁸. Wang et al., in 2015 produced six hypertrophic scars on each ear of rabbit¹³. Multiple hypertrophic scar models have not been reported in other animals. In the present study eight keloids have been produced in one animal.

The objective of this study is to find out effect of production of multiple keloids on health of the animal. The authors want to investigate if multiple keloids can be produced in one animal without causing any untoward effects on the health of that animal.

Methods

It was a quasi experimental trial, carried out at Experimental Research and Pathology Laboratories, University of Health Sciences, Lahore, Pakistan. Its duration was twelve months, from May 2011 to April 2012. Sample consisted of two New Zealand White rabbits. Sampling was done by simple convenience technique.

Approval was taken from institutional Ethical Review Committee. Universal protection was used i.e. surgical gown, surgical cap, surgical mask, surgical goggles, examination gloves, and surgical shoe covers. Surgical instruments were sterilized in hot air sterilizer at 160° C for 90 minutes. Surgeon washed-up with alcoholic surgical hand disinfectant, and wore surgical gloves.

Two rabbits were taken; one as control, and other as interventional. Interventional rabbit was anaesthetized with Ketamine injection (75 mg kg⁻¹ intraperitoneal), and Xylazine injection (15 mg kg⁻¹ intraperitoneal). Rabbit ear was sanitized with sterilized saline gauze and ethyl alcohol swab. Proposed point of keloid was marked on rabbit ear with gentian violet and Castroviejo calliper. In interventional rabbit eight keloids were produced, four on each ear, using Mannan & Hannan technique^{19,20}. Sites of keloids were as follows:

1. Right Ear Ventral Surface; Caudo-Proximal
2. Caudo-Distal
3. Cranio-Distal
4. Cranio-Proximal
5. Left Ear Ventral Surface; Caudo-Proximal
6. Caudo-Distal
7. Cranio-Distal
8. Cranio-Proximal

If bleeding occurred, it was controlled with mosquito artery forceps. If inadvertently dorsal skin was injured, it was stitched with 4/0 surgical silk. General

post-operative care was given. Analgesics were not required. Antibiotics were not used. General wound care was provided. If stitches had been applied, they were removed at one week. Dressing was permitted to drop itself. Keloids were examined at twenty eight days.

Results

Eight keloids were produced in one rabbit without causing any untoward effect on the health of that animal. Scar elevation index was 3.45 at 28 days, and 2.17 at 365 days. The animal was kept under observation regarding signs of discomfort, distress, stress, and suffering. These include pain, fever, anorexia, insomnia, irritability, aggressiveness, and others (Table 1). No change in behavior of our animal was observed (Table 2). No analgesics or antibiotics were needed. Special observation continued for four weeks, and animal remained well during this time.

Table 1: Signs of Distress in Laboratory Animals

Species	Posture	Voice	Tempera- ment	Loco- motion	Others
Mouse	Dormouse	Squeal	Docile	---	Eats Bedding
Rat	Dormouse	Squeal	Docile	---	Eats Bedding
Guinea Pig	---	Squeal	Quiet	Drags Hind Limbs	No Spillage of Food / Water
Rabbit	Hiding	Squeal	Dozey [sic]	---	No Spillage of Food / Water

Adapted from Morton & Griffiths (1985)²¹

Table 2: Signs of Distress Specific to Rabbits in our Study

Sr No	Sign	Yes or No	Remarks
1	Eyes open widely	No	No proptosis
2	Body becomes tense, tail moving up	No	Body relaxed
3	Ears are laid back tightly	No	Ears elevated
4	Animal growls or squeaks	No	No squeaking
5	Animal pushes hand away on touching	No	Cooperative
6	Animal lacks vitality or interest	No	Animal active
7	Animal flinches when touched	No	No flinching
8	Animal breathing becomes rapid	No	Breathing normal
9	Animal starts biting	No	No biting

Adapted from University of Minnesota Center to Study Human Animal Relationship and Environments (2016)²²

Keloids produced were considerable on examination. They were of solid consistency. They were of round shape, and their colour was red. They had a smooth surface, and were hairless. Keloids were present even after twelve months of follow-up (Figure 1).

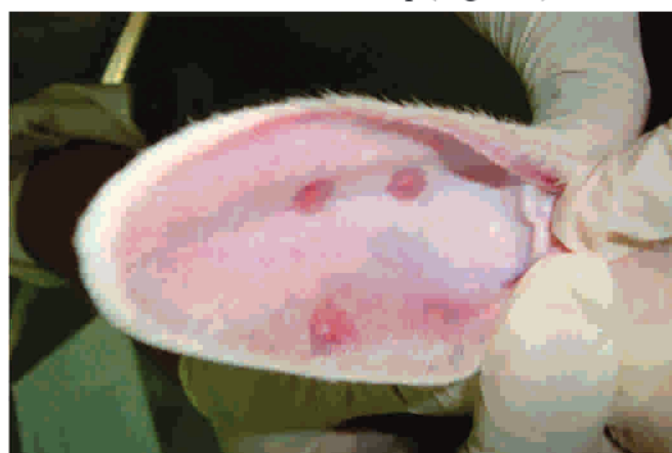

Figure 1: Multiple Keloids produced in one Rabbit

On gross examination, keloids were hard in consistency, and were palpated as discrete nodules. They were of red colour and their surface was smooth. They had a gritty feeling on cutting. On cut section, their surface was pale in colour. On microscopic examination, keloids showed glassy, hyalinized, homogeneous, brilliantly eosinophilic collagen. They contained a few fibroblasts, lying in direction of collagen (Figure 2).

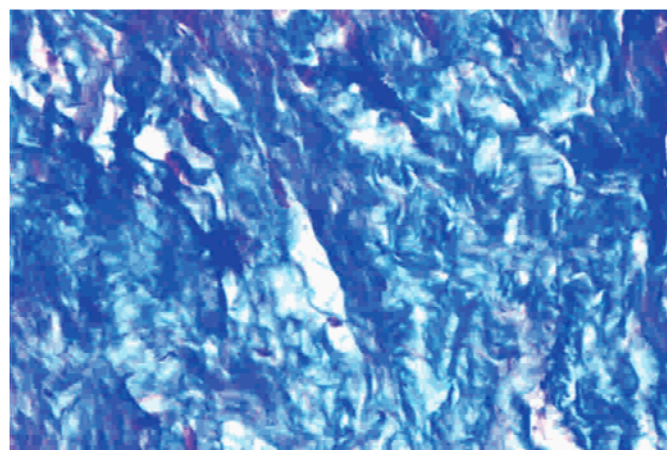


Figure 2: Microscopic View of Keloid with Periostrin stain

Discussion

The principles of the 3Rs (Replacement, Reduction and Refinement) were developed over half a century ago, as an agenda for humane animal research. These principles are now included in many national and

international regulations controlling the use of animals in scientific research. Replacement relates to methods to replace animal use with non-animal techniques. Reduction implies approaches to decrease number of animals utilized in one trial. Refinement means ways to reduce distress of animals. Reduction is especially relevant in this study as more information can be obtained from less number of animals, thereby decreasing number of animals used¹⁵.

There are multiple signs of stress or distress in animals. These signs include diarrhea, inappropriate micturition, increased salivation, decreased salivation, sneezing, coughing, shivering, shaking, restlessness, listlessness, agitation, biting, hiding, and yawning. Signs of distress specific to rabbits include the following: eyes open widely so that sclera becomes visible; body becomes tense with tail moving up; ears are laid back tightly; animal growls or squeaks; animal pushes hand away; animal lacks vitality or interest; animal flinches when touched; animal breathing becomes rapid; animal starts biting²². No sign of stress or distress was noted in rabbits in this study.

Hypertrophic scar animal models are usually produced by making one wound per animal. This has been due to fears about morbidity and mortality of the animals. Diao et al., in 2013 produced four hypertrophic scars on each ear of rabbit. They made 10 mm circular excisions of full thickness skin with scalpel blade. They left the wounds exposed to air. They had scar elevation index of 2.07 at 45 days. They did not report any untoward effects on rabbit¹⁷.

Xiao and Xi in 2013 produced three hypertrophic scars on each ear of rabbit. They used 5 mm biopsy punch, and excised skin and perichondrium. They used polyurethane dressing. They had scar elevation index of 1.73 at 14 days. No side effects were reported on health of animal¹⁸.

Wang et al. in 2015 produced six hypertrophic scars on each ear of rabbit. They used 7 mm biopsy punch, and excised skin and perichondrium. They had scar elevation index of 2.93 at 21 days. They were no adverse effects reported on health of animal¹³.

In the present study eight keloids have been produced in one animal. Our scar elevation index was 3.45 at 28

days, which is higher than all other studies. Our scar elevation index was 2.17 at 365 days, which has not been reported in other studies. Comparison of our study with previous ones is shown in Table 3. Multiple hypertrophic scar models have not been reported in other animals.

This study will open a further avenue for animal (and human also) research on treatment of keloids in future. This study will also reduce the use of laboratory animals in medical research. No doubt this is a small study, but in future it will lead to bigger studies on laboratory animal research, as well as on keloid therapy. This study also raises the question whether it can be replicated in other laboratory animals like Guinea pigs; only more research will answer this question.

Table 3: Comparison of Different Studies of Multiple Keloids

Author Parameter	Babar & Nagi, 2016	Diao et al, 2013	Xiao & Xi, 2013	Wang et al, 2015
No.	8	8	6	12
Size	8 mm	10 mm	5 mm	7 mm
Injection	TGFB1	Nil	Nil	Nil
Instrument	Biopsy Punch	Scalpel Blade	NR	Biopsy Punch
Tissues Excised	Skin, Ventral Perichondri um, Cartilage, Dorsal Perichondri um	Skin	Skin, Perichon -drium	Skin, Perichon -drium
Dressing	Hydrocolloi d	Nil	Polyuret hane	Nil
Time	28 days	45 days	14 days	21 days
Scar Elevation Index at 28 Days	3.45	2.07	1.73	2.93
Untoward Effects	Nil	NR	NR	NR
Duration	365 days	NR	180 days	NR
Scar Elevation Index at 365 Days	2.17	NR	NR	NR
NR = Not Reported TGFB1 = Transforming Growth Factor Beta 1				

Conclusion

Multiple keloids can be produced in one animal without causing any untoward effects on the health of that animal.

Ethical Approval: Given

Conflict of Interest: None

Funding Source: This Study was funded by Higher Education Commission, Govt. of Pakistan, Islamabad, Vide Project No. 20-1427/R&D/09

References

- Hunasgi S, Koneru A, Vanishree M, Shamala R. Keloid: A case report and review of pathophysiology and differences between keloid and hypertrophic scars. *J Oral Maxillofac Pathol* 2013;17: 116-120.
- TrislianaPerdanasari A, Lazzeri D, Su W, Xi W, Zheng Z, Ke L, Min P, Feng S, Zhang YX, Persichetti P. Recent developments in the use of intralesional injections in keloid treatment. *Arch Plast Surg* 2014; 41: 620-629.
- Ahuja RB, Chatterjee P, Deraje V. A critical appraisal of nonsurgical modalities for managing hypertrophic scars and keloids. *Formosa J Surg* 2015;48: 49-56.
- Sidgwick GP, McGeorge D, Bayat A. A comprehensive evidence-based review on the role of topicals and dressings in the management of skin scarring. *Arch Dermatol Res* 2015;307: 461-477.
- Rabello FB, Souza CD, Farina Jr CD. Update on hypertrophic scar treatment. *Clinics (Sao Paulo)* 2014;69: 565-573.
- Philandrianos C, Kerfant N, Jaloux Jr C, Martinet L, Bertrand B, Casanova D. Les cicatrices cheloides (premiere partie): unepathologie de la cicatrisation-cutanee {French} [The keloid scars (part one): a (sic) pathology of cutaneous wound healing]. *Ann Chir Plast Esthet*, doi: 10.1016/j.anplas.2015.09.005.
- Babar AM, Nagi AH. Keloid: Production of keloid animal model. *Prof Med J* 2016;23: 907-912.
- Babar AM, Nagi AH. A new technique for development of rabbit ear keloid model. *Pak J Zoo* 2017; 49: 379-382.
- Babar AM, Nagi AH. Mannan & Hannan Technique for production of rabbit ear keloid model. *The J Animal Plant Sci* 2017; 27: 1-5.
- Liu H, Yang HL, Zhou SF, Meng CY, 在癭痕成纖維細胞增殖及轉化生長因子 $\beta 1$ 和 α 平滑肌肌動蛋白的mRNA和蛋白表達IIA \square 酸 \square 丹參 \square 的影響 {Chinese} [Effects of sodium tanshinone II A sulfonate on proliferation of fibroblasts in scar and the mRNA and protein expressions of transforming growth factor beta 1 and alpha smooth muscle actin]. *Zhonghua Shao Shang ZaZhi = Chinese J Burns* 2013;29: 294-299.
- Chen Z., Li W, Ning Y, Liu T, Shao J, Wang Y. Ski diminishes TGF- $\beta 1$ -induced myofibroblast phenotype via up-regulating Meox2 expression. *Exp Mol Pathol* 2014;97: 542-549.
- Fan C, Dong Y, Xie Y, Su, Y, Zhang X, Leavesley D, Upton Z. Shikonin reduces TGF-beta1-induced collagen production and contraction in hypertrophic scar-derived human skin fibroblasts. *Int J Mol Med* 2015;36: 985-991.
- Wang H, Chen Z, Li XJ, Ma L, Tang YL. Anti-inflammatory cytokine TSG-6 inhibits hypertrophic scar formation in a rabbit ear model. *Eur J Pharmacol* 2015;751: 42-49.
- Russell WMS, Burch RL. The principles of humane experimental technique, Methuen, London 1959;ch: 6-8.
- NC3Rs. The 3Rs. Retrieved 08.09.2016, from <https://www.nc3rs.org.uk/the-3rs>.
- Understanding Animal Research. Animal welfare and the three Rs: Replacement, Refinement and Reduction. Retrieved 08.09.2016, from www.understandinganimalresearch.org.uk.
- Diao JS, Xia WS, Yi CG, Yang Y, Zhang X, Xia W, Shu MG, Wang YM, Gui L, Guo SZ. Histone deacetylase inhibitor reduces hypertrophic scarring in a rabbit ear model. *Plast Reconstr Surg* 2013;132: 61e-69e.
- Xiao Z, Xi C. Hepatocyte growth factor reduces hypertrophy of skin scar: in vivo study. *Adv Skin Wound Care* 2013;26: 266-270.
- Babar AM. Keloids and hypertrophic scars: Treatment with intralesional interferon gamma versus triamcinolone acetonide. PhD thesis, University of Health Sciences, Lahore, Pakistan 2015;pp: 445, 539-540.
- Nagi AH, Babar AM. Surgical adjuvant intralesional cytokines versus steroids for hypertrophic scars and keloids. Higher Education Commission Islamabad, Pakistan 2015; p: 15.
- Morton B, Griffiths PHM. Guidelines on the recognition of pain, distress and discomfort in experimental animals and an [sic] hypothesis for assessment. *Vet Record* 1985;116: 431-446.
- University of Minnesota Center to Study Human Animal Relationship and Environments. Signs of stress in companion animals. Retrieved 08.09.2016, from <http://www.censhare.umn.edu/public-service-projects/companion-animals-in-care-environments/signs-of-stress-in-companion-animals/>.