

## Research Article

### Foreign Bodies Presentation at Otorhinolaryngology Emergencies in A Tertiary Care Hospital

Taimoor Akram Khan<sup>1</sup>, Hafiz Mudabbar Mahboob<sup>2</sup>, Iqra Tahir<sup>3</sup>, Muhammad Nasir<sup>4</sup>, Asad Ali<sup>5</sup>, Irfan Abbas<sup>6</sup>, Ali Akram Khan<sup>7</sup>

<sup>1</sup>Demonstrator, Department of Community Medicine, King Edward Medical University, Lahore, <sup>2</sup>House Officer, Mayo Hospital, Lahore, <sup>3</sup>House Officer, Mayo Hospital, Lahore, <sup>4</sup>Demonstrator, Department of Community Medicine, King Edward Medical University, Lahore, <sup>5</sup>House Officer, Mayo Hospital, Lahore, <sup>6</sup>House Officer, Mayo Hospital, Lahore, <sup>7</sup>Demonstrator, Department of Community Medicine, King Edward Medical University, Lahore

#### Abstract

In Otorhinolaryngology emergencies, foreign body in ear, nose and throat (ENT) is a common presentation. The type, site and presenting symptoms of foreign bodies differ with the age group and gender of the patient.

**Objective:** To analyze foreign bodies in terms of age, location, type, gender distribution and correlation between age group of patients and location of foreign body.

**Methods:** It was a prospective survey conducted at ENT department of Mayo Hospital, Lahore from 1st August, 2017 to 31st October, 2017. The data collected was entered in SPSS 21 for description and analysis.

**Results:** 583 cases of foreign bodies in ENT region were reported. Mean age of presentation was 12.19 years with maximum age of 84 years and minimum age of 1 year. 331 cases (56.77%) were males and 252 cases (43.22%) were females. Predominant site was ear (342 cases i.e., 58.66%), then nose (182 cases i.e., 31.21%) and throat was the third commonest site (59 cases i.e., 10.12%). 401 patients out of 583 (68.78%) were below 10 years of age. Maximum patients at the time of presentation were 3 years old (110 cases out of 583 i.e., 19.89%). A strong association was seen between age of patient and site of foreign body impaction with a p-value of .0001.

**Conclusion:** Foreign body impaction in ENT region is a common emergency, reducing their incidence especially in children by educating their caregivers can help in decreasing patient load at tertiary care hospitals.

**Received** | 24-02-2018: **Accepted** | 28-08-2018

**Corresponding Author** | Dr. Taimoor Akram Khan, Demonstrator, Department of Community Medicine, King Edward Medical University, Lahore. **Email:** taimoorakramkhan@gmail.com

**Keywords** | Ear, Nose, Throat, Foreign Body, Otorhinolaryngologic Emergencies

#### Introduction

In Otorhinolaryngologic emergencies, foreign body in ear, nose and throat is a common presentation.<sup>1</sup> Either inserted or swallowed, foreign body impaction is common in all age groups.<sup>2</sup> The type and site of foreign body differs with the age group and gender of the patient.<sup>1</sup> Similarly, the presenting symptoms of the patients also vary with the nature

and location of foreign body.

Visualized and diagnosed by Anterior Rhinoscopy, Otoscopy examination, Flexible or Rigid Bronchoscopy and radiographs of the ENT region, foreign bodies are usually removed under local anesthesia but pharyngeal or tracheal foreign bodies require general anesthesia and surgical expertise.<sup>3</sup> The delayed

removal of foreign bodies can lead to various complications such as tissue necrosis, tissue scarring, granuloma formation, persistently discharging ear or nose, hoarseness of voice and stridor.<sup>3,4</sup>

The increasing number of patients visiting the emergency departments of health care facilities puts further burden on health care system. Otorhinolaryngology patients constitute a significant proportion of these cases.<sup>6</sup> Previously in Pakistan, similar studies regarding foreign bodies of Ear and Esophagus, their type, site of impaction and management have been carried out in Liaquat university hospital, Hyderabad and Ayyub hospital, Abbottabad, respectively.<sup>7,8</sup>

Mayo hospital Lahore is the largest tertiary care hospital in Pakistan with a capacity of 3000 beds.<sup>9</sup> This study was conducted at the ENT department of Mayo Hospital which provides otorhinolaryngology emergency facilities for 24 hours, in order to determine the types and location of foreign bodies impacted in the Ear, Nose and Throat regions. Furthermore the study will also help to study the correlation between the age group of patients and the site of foreign body impaction. The results obtained from this project will help us to assess the patient load due to foreign body impaction in ENT region which will ultimately help in proper placement of manpower and resources in order to prevent and treat such emergencies.

## Methods

This study was carried out in the emergency section of ENT department, Mayo Hospital, Lahore, Pakistan from 1st August 2017 to 31st October 2017. Written permission was obtained from the concerned authority prior to data collection. All the patients that presented with foreign body impaction to the ENT Emergency Mayo Hospital during this time period were included. The type and site of foreign bodies were investigated through relevant history, clinical examination and investigations according to the Otorhinolaryngologic guidelines by qualified ENT specialists. The data were entered and analyzed using SPSS version 21. Ages of patients were placed into categories and then all categorical variables were described by giving their frequencies and percentages. Chi-square test was applied to check the association between age groups of patients and the

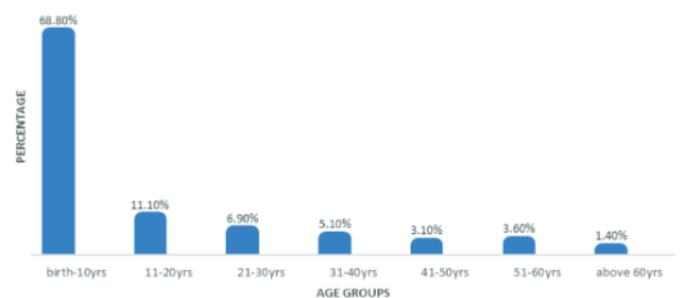
site of impaction of foreign body. Ethical considerations including patient confidentiality were observed.

## Results

In the study period of 3 months, 583 cases of foreign bodies in ENT region were reported. Mean age of presentation was 12.19 years with maximum age of 84 years and minimum age of 1 year.

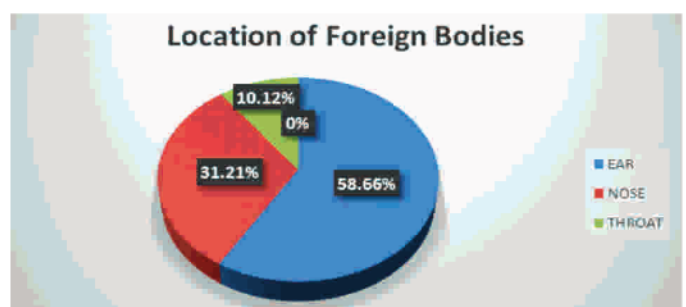
In terms of gender wise distribution, 331 cases (56.77%) were males and 252 cases (43.22%) were females, showing male dominance.

Patients who presented to the ENT emergency were placed in different age group categories of 10 years. 401 cases out of 583 (68.78%) were less than 10 years old. The age of maximum patients at the time of presentation was around 3 years (110 cases out of 583 i.e., 19.89%) Fig.1



**Fig.1:** Percentage of Patients in Each Age Groups

Foreign bodies were found in three distinct locations i.e., ear, nose and throat, but the predominant site was ear (342 cases i.e., 58.66%), second commonest site was nose (182 cases i.e., 31.21%) and throat being the third site (59 cases i.e., 10.12%). Fig. 2



**Fig.2.** Location of Foreign Bodies

Various types of foreign bodies were recovered from the ENT region, Pearls were the most common amongst them (127 cases i.e., 21.78%) and Common



pins were the least common (6 cases (1.02%))

On cross tabulating age groups of patients with the location of foreign body impaction it was seen that the predominant site of foreign body impaction varies with the age group of the patient. Ear was the most common site of foreign body impaction in patients below 50 years of age whereas throat was the most common site of foreign body impaction in patients above 50 years of age. No case of foreign body impaction in nose was seen in patients who were older than 50 years (Table 1). Chi-Square test was applied and a strong association was seen between the age group of patients and the site of impaction of foreign body with a p-value of .0001 and Chi-Square  $\chi^2=155.48$  at 12 degree of freedom.

## Discussion

ENT foreign bodies account for 11% of emergency cases which commonly present in otorhinolaryngology department<sup>10</sup>. These impose a considerable burden and constitute an important part of the daily sick report of hospitals. Foreign body impaction is common in both children and adults but the prevalence rate is higher in children<sup>3,11</sup>. In a study conducted in Malaysia, after suspecting foreign body insertion, 94% of cases presented immediately in the ER department and got FB removed within 24 hours of presentation.<sup>12</sup> Majority of the patients presenting

general anesthesia are required for their removal.<sup>5</sup>

In this study, male preponderance (56.78% cases v/s 43.22% cases) is in agreement with the commonly observed trend in international studies.<sup>10,12,13</sup> The greater incidence of foreign body impaction in males as compared to females was also reported by Shrestha et al.<sup>14</sup> Regarding foreign body insertion, this male dominance can be attributed to the aggressive behavior of males in handling and manipulation of different objects.

Most of FB cases (68.78%) presenting to the ER of ENT department were below 10 years of age. This finding represents the general curiosity of children to insert objects while playing in home or outside home into different orifices of body especially ear, nose and oral cavity. The maximum incidence of FBs in this age group and specifically in the ENT region is explained by the fact that during the oral stage of development, a child seeks pleasure through the manipulation of various natural orifices including the ear, nose and throat.<sup>13,15</sup> This finding followed the descending trend with advancing age. In teenagers, 60 cases (11.10%) were reported while 8.20% of the individuals presenting in ER belonged to the middle age group. Elders (51 years and above) constituted only 5% of the total cases.

The age structure and its relation to the location of FB in the study revealed that in the age group of below 10 years, ear was the commonest site involved (54.6% of cases), nose being the second most common site (41.4%) and throat the least (0.04%). In elderly (51 years and above), throat and ear were equally involved sites of impaction of foreign body and no case of foreign body impacted in nose was seen. This trend goes with the findings of other studies conducted across the globe.<sup>13,15</sup>

In this study, foreign body ear was preponderant i.e., 58.66% of total cases, followed by foreign body Nose i.e., 31.21% of all cases and foreign body throat i.e., 10.12% of cases. This finding is contrary to the findings of Mukherjee A et al and Ijaduola GTA et al where Nose was the commonest site of foreign body impaction.<sup>10,16</sup> The reason behind Ear being the commonest site of foreign body impaction is the higher prevalence of ear related diseases in our community.<sup>4</sup> Patients having ear diseases develop regular cleaning habit due to irritation and are more

**Table 1:** Cross Tabulation Between Age Group of Patients and Site of Impaction of Foreign Body

AGE GROUP OF THE PATIENT BIRTH -10 YEARS	LOCATION OF FOREIGN BODY			Total
	Ear	Nose	Throat	
<b>11-20 YEARS</b>	219(54.6%)	166(41.4%)	16(3.9%)	401
<b>21-30 YEARS</b>	52(80%)	6(9.2%)	7(10.7%)	65
<b>31-40 YEARS</b>	32(80%)	3(7.5%)	5(12.5%)	40
<b>41-50 YEARS</b>	17(56.7%)	4(13.33%)	9(30%)	30
<b>51-60 YEARS</b>	10(55.55%)	3(16.66%)	5(27.77%)	18
<b>ABOVE 60 YEARS</b>	8(38.1%)	0(0%)	13(61.9%)	21
<b>TOTAL</b>	4(50%)	0(0%)	4(50%)	8
<b>TOTAL</b>	342	182	59	583

with foreign bodies are asymptomatic but some of them present with pain, chronic discharge, dysphagia and stridor.<sup>3,11</sup> History, physical examination and radiological approach, all are necessary for the diagnosis of foreign body impaction. Both local and

prone to accidental entry of foreign body in ear, commonly cotton buds etc.<sup>2</sup>

Various types of foreign bodies like pearls, plastic pellets, stones, cotton pieces, insects, buttons, bone pieces, batteries, seeds, coins, lead pencil pieces, nut bolts and pins were recovered from the presenting individuals. 21.78% of cases presented with pearls impacted in the ENT region. Plastic pellets were the second commonest type of foreign body (17.32% of total cases) whereas Stones (11.7%), Cotton pieces (11.13%) and Insects (8%) were also amongst the most common types of foreign bodies recovered. In a study, Cotton pieces were the most frequently retrieved foreign body<sup>17</sup> while in two local studies in Pakistan, Beads were the commonest type of foreign body retrieved in the ENT emergency.<sup>18,19</sup>

### Conclusion

Otorhinolaryngology foreign body impaction is a common emergency especially in children. Knowledge of these foreign bodies can be helpful in educating the prime care givers, which can ultimately reduce the incidence of these cases and patient load in emergency departments of healthcare facilities thereby decreasing the morbidity, mortality and cost incurred on treatment of such problems.

**Ethical Approval:** Given

**Conflict of Interest:** None

**Funding Source:** None

### References

1. Ramesh P. Foreign Bodies in the Ear, Nose and Throat: An Experience in a Tertiary Care Hospital in Central Nepal. *Int Arch Otorhinolaryngol.* 2014; 19:121-123. d.o.i 10.1055/s-0034-1397336.
2. Rafique M, Shaikh AA, Siddiqui AH. Foreign Bodies in Ear - Its Type, Diagnosis and Management. *J LiaquatUni Med Health Sci.* 2015; 14(02):86-9.
3. Heim SW, Maughan KL. Foreign bodies in the ear, nose, and throat. *Am Fam Physician.* 2007 Oct 15; 76(8): 1185-1189.
4. Khan MA, Akram S, Ahmed A. Comparison of Ear, Nose and Throat disorders prevalent in pediatric and adult patients in Khawazakhela Swat, Pakistan. *Armed Forces Med J Pak.* 2015; 65:S223-6.
5. Pakistan. Pakistan bureau of statistics. Pakistan bureau of statistics Census 2017 results. Islamabad: Pakistan bureau of statistics; 2017 [cited 2017 Sep 26]. Available from: <http://www.pbscensus.gov.pk/>
6. Pakistan Medical and dental council [internet]. Islamabad: Pakistan Medical and Dental Council; 2015 [updated 2017 Mar 14; cited 2017 Sep 25]. Available from: <http://www.pmdc.org.pk/Statistics/tabid/03/Default.aspx>
7. Hafeez M, Zakirullah, Inayatullah. Foreign body nose in children presenting at a tertiary care teaching hospital in Pakistan. *Pak J Med Sci.* 2011; 27(1):124-127.
8. Asif M, Haroon T, Khan Z, Muhammad R, Malik S, Khan F. Foreign body esophagus: types and site of impaction. *Gomal J Med Sci.* 2013; 11:163-6.
9. Mayo Hospital [internet]. Lahore: Mayo Hospital; 2017 [updated 2017 Jan 5; Cited 2017 Sep 22]. Available from: <https://www.mayohospital.gov.pk/about.php#introduction>
10. Mukherjee A, Halder D, Dutta S, Dutta M, Saha J, Sinha R. Ear, nose and throat foreign bodies in children: A search for socio-demographic correlates. *Int J Pediatr Otorhinolaryngol.* 2011 Apr 30; 75(4): 510-2.
11. Ngo A, Ng KC, Sim TP. Otorhinolaryngeal foreign bodies in children presenting to the emergency department. *Singapore Med J.* 2005 Apr; 46(4):172-8.
12. Bloom DC. Plastic laryngeal foreign bodies in children: A diagnostic challenge. *Int J Pediatr Otorhinolaryngol.* 2005; 69:657-662.
13. Carney AS, Patel N, Clarke R. Foreign bodies in the ear and the aero digestive tract in children: Scott Brown's otolaryngology. 7th ed. Canada: Hodder Arnold Publishers; 2008.
14. Shrestha I, Shrestha BL, Amatya RCM. Analysis of Ear, Nose and Throat Foreign Bodies in Dhulikhel Hospital. *Kathmandu Univ Med J.* 2012; 38(2):4-8.
15. Mishra A, Shukla GK, Bhatia N. Aural Foreign bodies. *Indian J of pediatrics.* 2000; 67(4):267-269.
16. Ijaluola GTA, Okeowo PA. Foreign body in the ear and its importance: the Nigerian experience. *J Trop Paediatr.* 1986; 32(1):4-6.
17. Qadir W, Yousuf A, Rashid Rafiq D, Malik MA, Qazi SM. Foreign bodies in the ear: presentation and variation in management, our experience. *IJCRLS.* 2015; 4(9): 367-370.
18. Qadir W, Yousuf A, Rafiq R, Malik MA, Qazi SM. Foreign bodies in the Ear: presentation and variation in management, our experience. *IJCRLS.* 2015; 4(9):367-370.
19. Amjad M, Abbas N. Foreign bodies in ear in children. *Pak Paed J.* 1999; 23(2):61-62.