

ORIGINAL ARTICLE

FREQUENCY OF ACUTE RISE OF INTRAOCULAR PRESSURE FOLLOWING YAG LASER POSTERIOR CAPSULOTOMY

Muhammad Adnan Khan¹, Muhammad Tariq Khan¹, Ashfaq ur Rehman¹, Mohammad Idris², Muhammad Ayub Khan³

Departments of Ophthalmology, ¹Hayatabad Medical Complex, ²Lady Reading Hospital, Peshawar and ³Gomal Medical College, D.I.Khan, Pakistan

ABSTRACT

Background: Posterior capsular opacification (PCO) is the most frequent complication of cataract surgery. The objective of this study was to determine the frequency of acute rise of intraocular pressure (IOP) following Neodymium-Yttrium Aluminum Garnet (Nd:YAG) laser posterior capsulotomy.

Materials & Methods: This cross-sectional study was conducted in the Department of Ophthalmology, HMC, Peshawar, Pakistan, from July-December 2016. Sample size was 325 selected by consecutive sampling technique. Inclusion criteria were all patients having significant PCO after uneventful cataract surgery with intra ocular lens implant. Demographic variables were sex, age groups and age in years. Research variable was presence of acute rise of IOP following YAG laser capsulotomy. Pre-laser assessment included slit lamp examination and recording of IOP with Goldmann applanation tonometer by a single ophthalmologist. IOP was measured 3 hours after Nd:YAG laser capsulotomy. Rise in IOP was labeled when IOP was ≥ 5 mmhg from baseline. Mean \pm SD was used to express quantitative variables like age. Categorical variables were analyzed as frequency and percentage. Goodness-of-fit was applied to compare the frequency of acute rise in IOP between sample and population. SPSS-20 was used for data entry and its analysis.

Results: Out of 325 patients, 170(52.3%) were men and 155(47.7%) were women. The mean age of the sample was 44.92 ± 23.843 years. A total of 107(32.9%) patients were 20-39 years old whereas 218(67.1%) were 40-70 years. IOP was raised in 61 (18.8%) patients while in 264(81.2%) patients it was not raised. The frequency of acute rise in IOP after YAG laser capsulotomy was significantly different in sample compared to population.

Conclusion: Men were more than women, especially of old age. The frequency of acute rise in IOP after YAG laser capsulotomy was significantly different in sample compared to population.

KEY WORDS: Intraocular Pressure; Nd:YAG laser posterior capsulotomy; Posterior Capsular Opacification.

This article may be cited as: Khan MA, Khan MT, Rehman AU, Idris M, Khan MA. Frequency of acute rise of intraocular pressure following YAG laser posterior capsulotomy. Gomal J Med Sci 2018 Oct-Dec;16 (4):109-12. <https://doi.org/10.46903/gjms/16.04.1964>

INTRODUCTION

Posterior capsular opacification (PCO) is the most frequent complication of cataract surgery.¹⁻³ Incidence of PCO is about 18-50% by two years post-operatively.⁴ Postoperative capsular opacification is a multifactorial physiological consequence of cataract surgery. Opacification involving the central posterior capsule has a significant impact on high- and low-contrast acuity and low-contrast sensitivity. The

proliferation, migration and abnormal differentiation of residual lens epithelial cells and fibers in the capsular bag have been implicated in the pathogenesis of posterior capsule opacification. The incidence and severity of PCO correlates to the use of surgical techniques, intraocular lens (IOL) optic edge designs and IOL materials.

Advances in surgical techniques, IOL materials, and designs have reduced the PCO rate to quite an extent but it is still a significant problem.³ Posterior capsular opacification referred to as 'secondary cataract' or 'after cataract', develops over the clear posterior capsule a few months to a few years after an uneventful cataract surgery. Posterior capsular opacification results from the growth and abnormal proliferation of lens epithelial cells on the capsule at the time of cataract surgery. These cells migrate

Corresponding Author:

Dr. Muhammad Adnan Khan
Vitreoretina fellow
Department of Ophthalmology
Hayatabad Medical Complex
Peshawar, Pakistan
E-mail: adnandaur786@gmail.com

to the posterior capsule, where they approach the central visual axis and cause visual-axis obscuration, resulting in dimness of vision. The PCO has two forms, fibrous and pearl. Sometimes, a combination of both is also found. Clinically, it is seen as a wrinkling on the posterior capsule at the site of fusion of the anterior and posterior capsules. A histological examination of the fibrous PCO shows extracellular matrix accumulation and the presence of elongated myofibroblast cells positive to vimentin and α -smooth muscle actin. Standard treatment of PCO consists of making an opening in the central part of posterior capsule. The Neodymium: YAG (Nd:YAG) laser has been used for about 35 years to treat Posterior Capsular Opacification.

The complications of this procedure are raised intraocular pressure (IOP), corneal damage, ruptured anterior vitreous face, retinal detachment, cystoid macular edema, IOL damage, iris hemorrhage, uveitis, macular hole, posterior subluxation of the IOL into the vitreous cavity, and backward movement of the IOL with resultant anterior chamber deepening.⁵⁻⁷

The raised IOP is the most common complication amongst the complications. Different proposed mechanisms that has been given for the pressure rise following Nd: YAG laser treatment include the deposition of inflammatory cells and debris in the trabecular meshwork, forward movement of vitreous and trabecular meshwork damage by laser shock waves that causes decrease drainage capacity.⁸ This acute IOP increase may be high enough to cause loss of vision to hand motion or light perception only or become persistent to cause visual field defects.⁹

A similar local study reported that raised IOP was noted in 53 (35.81%) cases while IOP remained normal in 95 (64.19%) cases.¹⁰ Another study reported acute rise in IOP was seen up to 8.3%.¹¹

Although previously, studies were conducted on this particular topic reporting a wide range of raised IOP i.e. from 8.3%-35.8%^{10, 11} following Nd: YAG laser posterior capsulotomy for PCO in pseudophakic patients. In our setup, no such study was conducted so we planned this study so that we can find the exact frequency of acute raised IOP in our patients and treatment modalities to be considered to prevent severe visual loss due to raised IOP. The raised IOP is most common complication following Nd: YAG laser treatment¹⁰. Different proposed mechanisms include the deposition of inflammatory cells and debris in the trabecular meshwork, forward movement of vitreous and trabecular meshwork damage by shock waves produced by laser that causes decrease drainage capacity¹². This acute IOP increase may be high enough to cause loss of vision to light perception or become persistent to cause visual field defects¹³. The objective of this study was to determine the frequency of acute rise of IOP following Neodymium-Yttrium Aluminum Garnet (Nd:YAG) laser posterior capsulotomy.

MATERIALS AND METHODS

This descriptive, cross-sectional study was conducted in the Department of Ophthalmology, Hayatabad Medical Complex, Peshawar, Pakistan, which is a one of tertiary eye care center in Khyber Pakhtunkhwa, from July 2016 to December 2016. Sample size of 325 patients was calculated with 95% confidence level, 3% margin of error and taking acute rise in IOP in 8.3% patients under WHO software for sample size determination. Sampling technique was consecutive, non-probability. Inclusion criteria were all patients having significant PCO after uneventful cataract surgery with intra ocular lens implant. Exclusion criteria were patients having glaucoma, corneal disease, diabetic retinopathy and inflammatory disease, dislocated IOL, history of trabeculectomy and retinal detachment surgery.

After obtaining approval from postgraduate medical institute ethical committee, data was collected from Out-patient department. The purpose, procedure and possible complications were explained to every patient. Informed consent was taken from the patients. The demographic variables were sex, age in years and age-groups (20-39, 40-70). Research variable was presence of acute rise of IOP following YAG laser capsulotomy (yes, no). Pre-laser assessment included slit lamp examination and recording of IOP with Goldmann applanation tonometer. The Q-switched Nd: YAG laser was used to make a hole in the opacified posterior capsule by following standard procedure. Intraocular pressure was measured 3 hours after Nd: YAG laser capsulotomy. All the Nd: YAG laser posterior capsulotomies, pre and post laser IOP measurements were performed by a single ophthalmologist.

Rise in IOP was labeled when IOP was found 5 mmHg or more from baseline. Mean \pm SD was used to express quantitative variables like age. Categorical variables like age groups and presence of acute rise of IOP following YAG laser capsulotomy were calculated in the form of frequency and percentage. Chi-square goodness-of-fit test was applied to compare the frequency of acute rise in IOP between sample and population. SPSS-20 was used for data entry and its analysis.

RESULTS

Out of 325 patients, 170 (52.3%) were men and 155 (47.7%) were women with male to female ratio of 1:0.9. (Table 1)

Table 1: Sex distribution in sample & population undergoing YAG laser posterior capsulotomy in Peshawar, Pakistan (n=325)

| Sex | Frequency | %age | 95% CI of Proportion |
|-------|-----------|------|----------------------|
| Men | 170 | 52.3 | 46.8 - 57.7 |
| Women | 155 | 47.7 | 42.2 - 53.1 |

Table 2: Age group wise distribution in sample & population undergoing Yag laser posterior capsulotomy in Peshawar, Pakistan (n=325)

| Age-groups | Frequency | Percentage | 95% CI of Proportion |
|-------------|-----------|------------|----------------------|
| 20-39 years | 107 | 32.9 | 27.7 – 38.0 |
| 40-70 years | 218 | 67.1 | 61.9 – 72.2 |
| Total | 325 | 100.0 | -- |

Table 3: Frequency of patients having acute rise of intraocular pressure after Yag laser posterior capsulotomy in sample and population in Peshawar, Pakistan (n=325)

| Acute rise in Intraocular pressure | Frequency | Percentage | 95% CI of Proportion |
|------------------------------------|-----------|------------|----------------------|
| Yes | 61 | 18.8 | 14.5 – 23.0 |
| No | 264 | 81.2 | 76.9 – 85.4 |
| Total | 325 | 100.0 | -- |

Table 4: Frequency of patients having acute rise of intraocular pressure after Yag laser posterior capsulotomy in sample versus population in Peshawar, Pakistan (n=325)

| Acute rise in Intra-ocular pressure | Observed frequency | Expected frequency | O-E | (O-E) ² | (O-E) ² / E | Chi-square value | DF | P value |
|-------------------------------------|--------------------|--------------------|--------|--------------------|------------------------|------------------|----|---------|
| Yes | 61 | 10.16 | 50.84 | 2584.71 | 254.40 | 262.61 | 1 | <.00001 |
| No | 264 | 314.84 | -50.84 | 2584.71 | 8.21 | at alpha 0.05 | | |

The mean age of the sample was 44.92 ± 23.843 years with minimum and maximum age of 20 and 70 years (range =50 years). A total of 107 (32.9%) patients were 20-39 years old whereas 218 (67.1%) were 40-70 years. (Table 2)

Intraocular pressure was raised in 61 (18.8%) patients while in 264 (81.2%) patients it was not raised. (Table 3)

The frequency of acute rise in IOP after YAG laser capsulotomy was significantly higher in sample compared to population. (Table 4)

DISCUSSION

Shaikh A¹⁴ determined higher prevalence of raised IOP (28%) after YAG laser capsulotomy. In our study we found IOP was raised in 61 (18.8%) patients while in 264 (81.2%) patients it was not raised.

Khaznada MA.⁸ in his study evaluated the complications during and following YAG laser posterior capsulotomy. He showed that out of 320 eyes, only 30 (9.37%) developed IOL pitting, 10 eyes (4.68%) developed rise in IOP, 2 eyes (0.62%) showed rupture in anterior vitreous face, 2 eyes (0.62%) developed Cystoids Macular Edema (CME). The best corrected visual acuity (BCVA) of 6/9 – 6/6 was achieved in 310 eyes (96.87%); whereas only 10 eyes (4.68%) did not have significant improvement in visual acuity. Their results were also comparable with our findings.

In another study from India complications of YAG Laser capsulotomy were studied. Immediate and persistent IOP rise was seen in 39.5% patients.¹⁵

Another more recent study in 2014 evaluated the complications of YAG laser capsulotomy showing a variety of complications noted after YAG laser capsulotomy. Intraocular lens pitting was the most common complication seen in 56 eyes (12.81%). Transient rise of IOP was seen in 38 eyes (8.69%) and cystoid macular edema was seen in 17 eyes (3.89%). Serious complications such as retinal detachment and endophthalmitis were seen in 2 eyes (0.45%) and 1 (0.22%) eye respectively.¹⁶

One other local study evaluated the complications of YAG laser when applied in post-op posterior capsule Opacification, following extra capsular cataract extraction with IOL. They reported raised IOP seen in 7 cases (5.83%)¹⁷. Their findings were showing IOP rise in less percentage of patients than compared to our study. Karahan E.¹⁸ studied the influence of capsulotomy size on IOP and macular thickness. In both groups, IOP increased 1 week after YAG capsulotomy ($p = 0.024$, $P = 0.001$, respectively). All of the patients with IOP elevation were treated successfully with anti-glaucoma medications.

CONCLUSION

Men were more than women, especially of old age. The frequency of acute rise in IOP after YAG laser capsulotomy was significantly different in sample compared to population.

REFERENCES

- Stein JD. Serious adverse events after cataract surgery. *Curr Opin Ophthalmol* 2012;23(3):219-25. <https://doi.org/10.1097/ICU.0b013e3283524068>

2. Muammar A, Al-Harkan D, Al-Rashidy S, Al-Suliman S, Mousa A. Frequency of retinal detachment after cataract surgery in highly myopic patients. *Saudi Med J* 2013;34(5):511-7
3. Awasthi N, Guo S, Wagner B. Posterior capsular opacification: a problem reduced but not yet eradicated. *Arch Ophthalmol* 2009;127(4):555-62. <https://doi.org/10.1001/archophthalmol.2009.3>
4. Khanzada MA, Gul S, Dabir SA, Jatoi SM, Narsani AK. Comparative incidence of posterior capsular opacification in AcrySof and PMMA intraocular lenses. *Int J Opth* 2009;2(2):150-3.
5. Ozkurt YB, Sengör T, Evciman T, Haboğlu M. Refraction, intraocular pressure and anterior chamber depth changes after Nd: Yag laser treatment for posterior capsular opacification in pseudophakic eyes. *Clin Exp Optom* 2009;92(5):412-5. <https://doi.org/10.1111/j.1444-0938.2009.00401.x>
6. Murthy G.V, Vashist P, John N, Pokharel G, Ellwein LB. Prevalence and causes of visual impairment and blindness in older adults in an area of India with a high cataract surgical rate. *Ophthalmic Epidemiol* 2010;17(4):185-95. <https://doi.org/10.3109/09286586.2010.483751>
7. Rasool W, Raza A, Ali SI. Efficacy of laser capsulotomy in the treatment of posterior capsule opacification. *JRMC* 2010;14(2):78-80.
8. Khanzada MA, Jatoi SM, Narsani AK, Dabir SA, Gul S. Is the Nd: Yag laser a safe procedure for posterior capsulotomy. *Pak J Ophthalmol* 2008;24(2):73-8.
9. Burq MA, Taqui AM. Frequency of retinal detachment and other complications after neodymium: Yag laser capsulotomy. *J Pak Med Assoc* 2008 Oct;58(10):550-2.
10. Waseem M, Khan HA. Association of raised intraocular pressure and its correlation to the energy used with raised versus normal intraocular pressure following Nd: Yag laser posterior capsulotomy in pseudophakes. *JCPSP* 2010;20(8):524-7.
11. Javed EA, Zahid Z, Sultan M. Nd: Yag laser capsulotomy and complications. *Professional Med J* 2007;14(4):616-9.
12. Singhal D, Desai R, Desai S, Shastri M, Saxena D. Use of topical brimonidine to prevent intraocular pressure elevations following Nd: Yag-laser posterior capsulotomy. *J Pharmacology Pharmacotherapeutics* 2011;2(2):104- <https://doi.org/10.4103/0976-500X.81902>
13. Galanopoulos A, Goldberg I. Clinical efficacy and neuroprotective effects of brimonidine in the management of glaucoma and ocular hypertension. *Clinical Ophthalmol* 2009;3:117. <https://doi.org/10.2147/OPHTH.S3270>
14. Shaikh A, Shaikh F, Adwani JR, Shaikh ZA. Prevalence of different Nd: Yag Laser induced complication in patients with significant posterior capsule opacification and their correlation with time duration after standard cataract surgery. *Int J Med Sci* 2010;2(1):012-7.
15. Gore V. The Study of complications of Nd: Yag Laser capsulotomy. *Int J Bioinformatics Res* 2012;4(2):265-8. <https://doi.org/10.9735/0975-3087.4.2.265-268>
16. Khan B, Alam M, Shah MA, Bashir B, Iqbal A, Alam A. Complications of Nd: Yag Laser Capsulotomy. *Pakistan J Ophthalmol* 2014;30(3):134.
17. Javed EA, Sultan M. ND: Yag laser capsulotomy and complications. *Professional Med J* 2007;14(4):616-9
18. Karahan E, Tuncer I, Zengin MO. The Effect of ND: Yag laser posterior capsulotomy size on refraction, intraocular pressure, and macular thickness. *J Ophthalmol* 2014;20-4. <https://doi.org/10.1155/2014/846385>

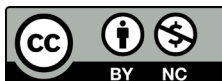
CONFLICT OF INTEREST

Authors declare no conflict of interest.
GRANT SUPPORT AND FINANCIAL DISCLOSURE
None declared.

AUTHORS' CONTRIBUTION

The following authors have made substantial contributions to the manuscript as under:

| | |
|--|------------------------|
| Conception or Design: | MAK |
| Acquisition, Analysis or Interpretation of Data: | MAK, MTK, AUR, MI, MAK |
| Manuscript Writing & Approval: | MAK, MTK, AUR, MI, MAK |
| All the authors agree to be accountable for all aspects of the work in ensuring that questions related to the accuracy or integrity of any part of the work are appropriately investigated and resolved. | |



Copyright © 2020 Muhammad Adnan Khan, This is an Open Access article distributed under the terms of the Creative Commons Attribution-Non Commercial 4.0 International License, which permits unrestricted use, distribution & reproduction in any medium provided that original work is cited properly.