

EFFECT OF HEAVY METALS (ZINC AND CADMIUM) ON SERUM ENZYMES ACTIVITIES AND RELATIVE WEIGHT OF LIVER AND KIDNEYS OF PIGEON, *COLUMBA LIVIA DOMESTICA*

Shahid Hussain* and Rahila Tabassum

Department of Zoology, University of Karachi, Karachi-75270, Pakistan.

*Correspondent author ghn.shahid@gmail.com

ABSTRACT

The alteration in the serum biochemical parameters are strongly associated with the health status of birds, and have assessed to check the health ailment against the heavy metal toxicity. Blood samples were collected from different groups of pigeons after 48 h of the low dose (10 µg/g) and high dose (20 µg/g). The mean level of alanine aminotransferase (ALAT), aspartate aminotransferase (ASAT), alkaline phosphatase (ALP), Uric acid and Creatinine was highly fluctuated with the low dose of cadmium (Cd-L), high dose of cadmium (Cd-H) and high dose of Zinc (Zn-H) whereas low dose of zinc (Zn-L) showed less impact on enzymes activities i.e., Cd-H > Cd-L > Zn-H > Zn-L. The pigeons of control groups exhibited high significance difference ($P < 0.05$) with treated group except of Zn-L group pigeons. The range (mean \pm S.D) of relative weight (g) of liver was high with Cd-L groups pigeons as compared to other groups i.e., Cd-L > Cd-H > Zn-L > Zn-H. The trend of relative weight (%) for paired kidney was Cd-L > Cd-H > Zn-H > Zn-L. The alteration in activities of enzymes and relative weight showed significance difference ($P < 0.05$) with low and high dose of cadmium and zinc. The level of serum enzymes activity increased significantly with low and high dose of cadmium and exhibited its high toxicity as compared to the Zinc.

Key Words: Heavy metals, Zinc, Cadmium, enzymes activity, pigeons, relative organ weight.

Abbreviations:-

ALAT = Alanine aminotransferase

ASAT = Aspartate aminotransferase

ALP = Alkaline phosphatase

Zn-L = Low dose of Zinc

Zn-H = High dose of Zinc

Cd-L = Low dose of Cadmium

Cd-H = High dose of Cadmium

ATSDR = Agency for Toxic Substances and Disease Registry.

INTRODUCTION

Birds are considered as befitting and excellent fauna for assessing the induced effect of toxic and trace metals, check the noxious level in the atmosphere as well as very important responsive indicators of contamination and their effluence in the surrounding (Godshe *et al.*, 2012; Kaur and Dhanju, 2013; Raza *et al.*, 2017). It was observed that the ever-increasing heavy metals contaminants in the environment showed significant impact and their lethal effect was alarming dilemma of growing concern for conservation, natural balance, health, nutritional, pertinent ecology and environmental perspective (Jaishankar *et al.*, 2014). The large fraction of heavy metals was reported in atmosphere comprises Lead, Cadmium, Nickel, Copper, Chromium, and zinc that are toxic to the birds, animal, plants and the ecological environment (Morais *et al.*, 2012). The heavy metal releasing in the environment through different processes consists of natural rocks weathering, mountain weathering, earth's crust weathering, continuous soil erosion, urban runoff, mining activities, use of insecticides, herbicides, rodenticides, agrochemical, dyes manufacturing, paint industry, plastic, batteries, electroplating, industrial effluent, organic waste, improper sewage disposal, burning of fossil fuel, non-exhaust automobiles emission and many others (Kibria, 2018; Ventura *et al.*, 2017).

Conferring to Agency for Toxic Substances and Disease Registry (ATSDR), the Cadmium is ranked as the 7th highly toxic, non-essential and noxious heavy metals. The deposition of cadmium in fauna and flora from different sources have been increasing, one of the prominent and possible means was zinc smelters (Lane *et al.*, 2015). It was further reported that the population of human and animals are exposed to the Cadmium through air, potable water, foodstuff contaminated with cadmium, and they deposited gradually in their bodies (Jarup and Akesson, 2009). It

was reported that the serum alanine aminotransferase, aspartate aminotransferase, alkaline phosphatase, urea, uric acid and creatinine released after the inflammatory cell infiltration, tubular necrosis and cloudy swelling of tubules as well as renal failure (Renugadevi and Prabu, 2010). In order to cut down Cd toxicity in the body of animals, oxygen supply immediately, efficient mechanical ventilation and proper fluid elimination were highly suggested (ASTDR, 2017). Toxicity of non-essential heavy metals cadmium were chief caused of acute and chronic cadmium poisoning by their deposition in birds, fishes and mammals via food chain in the natural environment (Sun and Xing, 2016). Cadmium exposure imposed voluminous toxic and injurious effects on animals and birds. Ailment in the important biochemical functions, physiological turbulence and structural mutilation of various vital organ including bones, liver, lungs, kidney, testis, pancreas and testis are due the toxic action of cadmium metals within the body of animal (Sarkar *et al.*, 2013).

Zinc is categorized as an important essential trace element and plays vital role in the biological functions of several proteins in the body likewise contributes in the enzymatic actions of cells (Maity *et al.*, 2008). Based on the unique reactive mechanism and comparison of several other essential and nonessential metals with similar chemical properties, zinc was considered as relatively less harmful. Furthermost exposure to long term, high dose zinc supplementation and acute intoxication inhibit with the uptake of copper from food (Laura *et al.*, 2010). One of the critical metallic fume illness was generally connected with zinc inhalation through brass plating, dyes, electroplating, galvanizing and welding process. Zinc Oxide and Zinc Chloride were potential health risk in the vicinity where they used frequently. It has significant interaction with the workers exposed to these oxides and chlorides (Bodar *et al.*, 2005). In addition to this, zinc was also fall in the category of a common impurity in agricultural and food waste. The emission of zinc in the natural environment due the anthropogenic activities including the combustion of fossil fuel by automobiles and others means, similarly coal fly ash are chief contributors globally (Laura *et al.*, 2010). The common illness caused by excessive and acute zinc exposure include ataxia, lethargy, slanginess, and interference with the absorption of copper and essential trace metal iron (Piao *et al.*, 2003). Continuous exposure to the Zn alters the level of enzymes including ALAT, ASAT, ALP, creatinine and uric acid (Abdel-Khalek *et al.*, 2015).

Proper examinations of serum biochemical parameters are viable and recommended to recognize the target organ toxicity, general health and fitness of animal (Jacobson-Kram and Keller, 2001). Serum biochemicals of blood are the chief products of intermediate metabolism and intimate the physiological condition of an animal (Artacho *et al.*, 2007).

MATERIALS AND METHOD

Experimental Birds

The metropolitan sedentary bird pigeon (*Columba livia domestica*) employed in this study. The mature adult Pigeons were purchased from local market (Sadder) of Karachi, Sindh. In order to assure their adjustment and acceptance, all the experimental birds were kept under cage in natural light condition and had auditory, visual contact, normal condition of feeding, free access to the water and proper ventilation. Health condition was examined by means of physical body language and activities of the birds.

Experimental Design and Groups

The low dose (10 µg/g) and high dose (20 µg/g) of heavy metals were formulated after preliminary testing. The experiment was lasted for two years and pigeons were exposed to low and high dose of cadmium and zinc by intramuscular injection 7th times after regular interval of ten days. Pigeons were fed properly three times, morning, noon and evening time with mix grain feed consist of wheat, crush rice, grain and bean etc. In order to sustain hygienic condition, cage were washed and cleaned properly after an interval of ten days. Mortality of the birds was determined carefully during experimental period. Pigeons were divided into five groups and each group consists of 10 birds details are as follows

Control group: The pigeon of this group were not subjected to the dose administration of heavy metals.

Zinc Low dose (Zn-L) group: The Pigeons were exposed to low dose (10 µg/g) of Zinc.

Zinc High dose (Zn-H) group: The Pigeons were exposed to high dose (20 µg/g) of Zinc.

Cadmium Low dose (Cd-L) groups: The Pigeons were exposed to low dose (10 µg/g) of Cadmium.

(Cd-H) groups: The Pigeons of this group were exposed to high dose (20 µg/g) high dose of Cadmium.

Enzymatic activity and relative weight analysis

Blood samples were taken from brachial vein and collected into yellow cap or gel tube containing acid citrate dextrose additives (ACD) for enzymes activities and blood was centrifuged at 3000 rpm for ten minutes. The level

of serum ALAT (u/L) and ASAT (u/L) was determined by following the protocol of International Federation of Clinical Chemistry (Henderson and Moss, 2001), similarly ALP (u/L) by method of Scherwin (2003) and uric acid by Newman and Price (1999) whereas level of creatinine determined by Jaffe method (Newman and Price, 2001).

The commercially available kit ALAT (Merck, Catalog# 5.17531), ASAT (Merck, Catalog# 5.17521), ALP (Merck, Catalog# 5.17641), Creatinine (Merck, Catalog# 5.17551) and Uric acid (Merck, Catalog# 5.17545) used to determine enzymes activities.

Birds were slaughtered to assess the relative weight (%) of liver and kidney by using the formula

$$\text{Relative weight (\%)} = \frac{\text{Weight of Organ}}{\text{Weight of Body}} \times 100$$

Statistical Analysis

All the statistical data were analyzed with IBM SPSS (version 21.0). The values are showed as mean \pm SD for biochemical and physical parameters, normal distribution of all variables was checked. ANOVA (Analysis of One-Way Variance) was applied to check the significance of data, groups mean were compared by Tuckey HSD test. P value less than 0.05 were considered as significant.

RESULTS

Table 1 showed the level of serum enzyme ALAT (u/l), ASAT (u/l), ALP (u/l), creatinine and uric acid of the pigeon in controlled group and treated group exposed with low dose (10 μ g/g) and high dose (20 μ g/g) of cadmium and zinc. The upsurge in the enzymes activities in treated group observed due to the toxicity of heavy metals zinc and cadmium. The pigeons of control groups and treated group showed dynamic interaction significantly ($P < 0.05$) except of Zn-L group. The multiple comparison analysis displayed high significance difference ($P < 0.05$) between enzymes activities and treated dose.

The serum ALAT level in control group Pigeons ranged 11.640–18.624 (u/L) whereas Zn-L groups range was 15.715–24.287 (u/L), similarly Zn-H, Cd-L and Cd-H group showed 30.716–39.288 (u/l), 61.432–84.291 (u/L), and 80.719–90.006 (u/L) respectively. The serum ASAT level in Pigeons of control group ranged 11.058–19.788 (u/L), Zn-L groups showed 15.001–27.145 (u/L), similarly Zn-H, Cd-L and Cd-H group showed 50.003–60.004 (u/L), 79.291–99.292 (u/L), and 122.151–144.295 (u/L), respectively. The serum ALP level in control group, Zn-L groups, Zn-H, Cd-L and Cd-H group ranged 16.50–31.167 (u/L), 31.667–57.750 (u/L), 92.583–109.083 (u/L), 182.416–297.917 (u/L), and 320.333–349.25 (u/L), respectively. The level of ALP was slightly fluctuated in Pigeons of Zn-L group as compared to the other treated groups. The trend of serum ALAT, ASAT and ALP augmentation was Cd-H > Cd-L > Zn-H > Zn-L Table 1.

Concerning serum creatinine and uric acid level, they exhibit a significant difference among different groups of control and treated group. These test are useful to identify the renal damage of heavy metals. The control group showed significant difference with all group or vice versa, whereas the significant relation ($P < 0.05$) decreased between Zn-H and Cd-L group. Creatinine in control group of pigeon ranged 0.2–0.4 (mg/dL), while Pigeons of group Zn-L, Zn-H, Cd-L and Cd-H showed 0.222–0.333 (mg/dL), 0.40–1.00 (mg/dL), 0.667–1.33 (mg/dL) and 2.00–3.00 (mg/dL), respectively. The serum Uric acid (mg/dL) level in control group ranged between 1.594–3.383 whereas Zn-L groups range was 3.22–4.25, similarly Zn-H, Cd-L and Cd-H group showed 4.595–6.567, 3.739–5.600, 6.195–8.603, respectively. It clearly pictured that serum uric acid level was high with the group Zn-H, Cd-L and Cd-H group and they are significant ($P < 0.05$) to each other. The trend of serum creatinine was Cd-H > Cd-L > Zn-H > Zn-L whereas serum uric acid showed Cd-H > Zn-H > Cd-L > Zn-L Table 1.

Table 2. Showed the relative weight (mean and S.D) of liver and paired kidney weight in pigeon of Control group and treated group (Zn-L, Zn-H, Cd-L and Cd-H). It was observed that the relative weight of pigeons among different group was changed due to the exposure with different dose of heavy metals and they established highly significance with each other. The maximum relative weight of Liver for control group pigeons was 2.059 ± 0.056 whereas Zn-L, Zn-H, Cd-L and Cd-H groups showed 2.709 ± 0.289 , 2.634 ± 0.208 , 2.988 ± 0.257 , and 3.297 ± 0.392 , respectively. The relative weight of liver was highly affected zinc and cadmium i.e., Cd-H > Cd-L > Zn-L > Zn-H. The maximum relative weight of paired kidney recorded for control group pigeons, Zn-L, Zn-H, Cd-L and Cd-H groups was 0.571 ± 0.022 , 0.779 ± 0.073 , 0.775 ± 0.059 , 0.948 ± 0.801 , 1.068 ± 0.150 , respectively. The trend of paired kidney weight of pigeons was recoded with treated groups of pigeons as Cd-L > Cd-H > Zn-H > Zn-L Table 2.

The dose concentration exhibited non-significance difference among pigeons of Zn-H with Zn-L and Cd-H for relative weight of liver, similarly Zn-L group developed non-significant relation with control and Zn-H group.

During the experimental period, there was no mortality observed in control group while mortality occurred in treated groups i.e., Cd-H > Cd-L=Zn-H > Zn-L Fig. 1.

Table 1. The level of serum enzyme ALAT, ASAT, ALP, Creatinine and Uric acid.

S.No.	Experimental Groups	Level of Serum Enzyme Activities N=150				
		ALAT (u/L)	ASAT (u/L)	ALP (u/L)	Creatinine (mg/dL)	Uric Acid (mg/dL)
1.	Control Group	15.520 ± 2.432	14.0383 ± 3.068	24.750 ± 5.561	0.292 ± 0.068	2.346 ± 0.588
2.	Zn-L Group	19.286 ± 3.130	21.0728 ± 5.674	40.027 ± 9.729	0.293 ± 0.048	3.693 ± 0.397
3.	Zn-H Group	36.073 ± 3.312	54.765 ± 3.489	101.291 ± 5.961	0.645 ± 0.224	5.792 ± 0.743
4.	Cd-L Group	69.694 ± 8.333	90.005 ± 7.171	238.180 ± 46.929	0.933 ± 0.265	4.527 ± 0.662
5.	Cd-H Group	86.672 ± 3.341	134.651 ± 7.782	335.569 ± 12.331	2.502 ± 0.331	7.605 ± 0.867

ALAT = Alanine aminotransferase ; ASAT = Aspartate aminotransferase; ALP = Alkaline phosphatase

Table 2. Measurement of body weight, relative liver and paired kidney weight of the pigeon.

S.No.	Experimental Groups	Final Body Weight	Relative Weight (%), $\Sigma N=100, n=10$		
			Liver Weight (%)	Paired Kidney Weight (%)	P-value
1.	Control Group	239.6± 14.119	1.993 ± 0.056	0.537 ± 0.022	0.000
2.	Zn-L Group	309.6± 25.851	2.235 ± 0.289	0.604 ± 0.073	0.000
3.	Zn-H Group	305.6±25.827	2.231 ± 0.208	0.653 ± 0.059	0.000
4.	Cd-L Group	276.9±33.888	2.534 ± 0.257	0.815 ± 0.801	0.000
5.	Cd-H Group	291.5±33.230	2.485 ± 0.392	0.813 ± 0.150	0.000

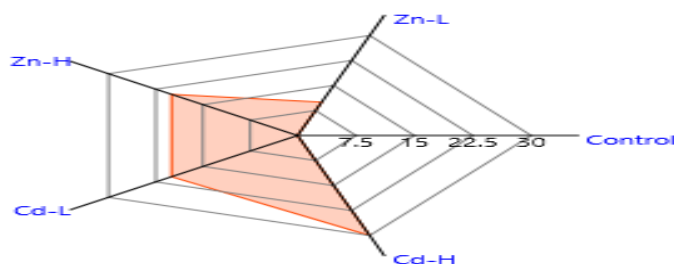


Fig. 1. Percent Mortality in Pigeons of Control and treated group.

DISCUSSION

Environmental contamination is emerging global health concern due to the emanation of heavy metals by anthropogenic activity. Cadmium and zinc are recognized to produce different injurious symptoms in the perilous targeted organ such as kidney and liver of birds. The current study was designed to measure the extent of toxicity of zinc and cadmium on liver and kidney after exposure to heavy metals. Hepatic tissue injuries, nephric tissue damage, liver dysfunctional and kidney failure occurred by cadmium and zinc beyond the permissible range. Furthermore, voluminous researches display a resilient association among heavy metals with liver and kidney. Nephrotoxicity is observed by the exposure of acute dose of heavy metals (Karimi *et al.*, 2012; Younis *et al.*, 2012).

Current study showed similar results that the increased level of ALAT, ASAT and ALP enzymes was due to the hepatic and pancreatic tissues damage. This was confirmed by close histopathological examination of the hepatic organ that exhibited absolute hepatic tissue injuries and enhanced serum enzymes activities linked with abnormal physiological ailment. The raised level of ALAT and ASAT seem in serum when impairment occurred in the tissue of liver and muscle due to excessive stress under heavy metals (Uyanik *et al.*, 2001). In line with these results, we observed the tissue damages in different groups of pigeons when treated with heavy metals at different concentrations.

The enzymes ASAT, ALAT and ALP were considered as pathological indicator enzymes, fluctuation in their level was keys for diagnosing the tissue injuries, diseases and/or environmental pollution stress. The listed enzymes are found in different organ of the body include bones, kidney, liver etc. The level of ALAT and ASAT were considered as potential key indicator enzymes for hepatic injury, their level in serum of blood is upsurge when hepatic tissue injury occurred (Kori-Siakpere *et al.*, 2012). The present study indicated that ALAT, ASAT and ALP activities in blood serum of Pigeons were significantly ($P < 0.05$) high among the pigeon of treated group as compared to the control group during experimental period. This fluctuation of the enzymes signifies the hepatic and muscular tissue damage. The ALAT enzymes in serum of birds used to diagnose the liver injuries due to environmental stress by contamination or treated with toxic chemical or heavy metals, this enzyme drained in the serum immediately when the hepatocellular injuries occurred (Orlewick and Vovchuk, 2012).

Trace element Zinc is micronutrient for the growth of animal but excess amount produce adverse effects in different organs and increased the enzyme activities in blood serum. The augmented level of serum ALAT, ASAT and ALP showed significance difference ($P < 0.05$) among all treated groups in relation to the control group and this augment was more effective with high dose. This depiction was meet with the finding of Fazilati (2013) who observed the elevation in ALAT and ASAT with exposure to trace metal Zinc. It was reported that Zinc supplementation upsurge the level of alkaline phosphatase (Al-Daraji and Amen 2011). It was also found that the level of ALP enhance progressively with increasing the zinc supplementations. Zinc metal being as an essential part of ALP enzymes, upsurge the ALP activity due to the results of unconventional bioavailability of organic matter (Nagalakshmi *et al.*, 2015). The birds with exposed to zinc 20 mg/kg showed high ALP activity with no significant effects on Liver enzymes (ALAT and ASAT) activities in relation to the control group (Fathi *et al.*, 2016). These observation plot conformities with the current study design but it showed divergence with those indicated by Persky and Brazeu (2001).

The cadmium metal regarded as non-essential trace metal for birds and considered as highly noxious to the plants and animals (Zhuang *et al.*, 2016). It is produce from different sources i.e., industrial waste, cigarettes smoke, burning of e-waste etc. to the environment resulting environmental pollution by heavy metals (Kant *et al.*, 2011). It was observed that the liver enzymes (ALAT, ASAT and ALP) activities was boosted due to the liver cells damage, consequently production of these enzymes increased by hepatic tissues (Wu *et al.*, 2003). It was reported that the sub-chronic dietary heavy metal exposure with time-dose relation prone more effect on liver enzymes following the elevation in serum ALAT and ASAT level with increasing dose concentrations over the time. They found that the releasing of these enzymes into the blood was main cause of the hepatic tissue damage by heavy metals. Due to the hepatic cells damage by the exposure of heavy metal, the serum enzymes activities augmented in treated animal (Kim and Kang, 2004). The treated pigeons with Cd-L, Cd-H and Zn-H showed fluctuation in the enzymes activities significantly ($P > 0.05$) as compared to the control group. The current findings displayed similarity to the cadmium exposure experiment at different time-dose relations and indicated the enhancement of level of serum ALAT with ASAT significantly (Abou-Kassem *et al.*, 2016).

Analogous result are reported when experimented birds were exposed to short and long-term sub-lethal dose of Zinc, this occurred due to accumulation of zinc in liver caused the liver tissue injuries subsequently liberation of these enzymes into the blood stream (Younis *et al.*, 2012). The elevated level of ALP and transaminases are signifying the necrotic changes in organ and tissue of the animals. The current study is line with the observation of Mohajeri *et al.*, 2014. The level of ALAT and ASAT in different pigeons was found to be high due to the damage of hepatic tissues. There were significant relation observed among the pigeons of control and treated group. This study is meet the findings of Bharavi *et al.* (2010) who reported the liver injury and high level of ALAT and ASAT in broilers birds treated with cadmium as compared to the control group.

The level of creatinine and uric acid in serum of birds are considered as basic parameters to indicate the glomerular filtration efficiency and normal physiology of kidney. The current result indicated an elevation in serum creatinine and uric acid in pigeons exposed to Zinc high dose when compared with the control group of birds. This is in accordance with the finding of Abdel-Tawwab *et al.* (2011) who reported the elevation in serum creatinine and uric acid when animal was treated with increasing concentrations of Zinc or repeated long term exposure. The preceding research design reported that the cadmium as well as zinc were prone to tissue injuries especially renal

damages (Van-Dyk *et al.*, 2007). Studies confirmed that the deposition of heavy metals in liver, kidney, heart and muscles of animal produced structural modification and histopathological injuries comprising cardiac disease, muscular disease hepato-nephro-pathological toxicity (Kar *et al.*, 2015).

The body weight of pigeons among different groups showed fluctuation, the weight lost was high with Cd-H dose as compared to the Cd-L and Zn-H, Zn-L and control groups. Similar weight lost results was obtained when cadmium intoxicated in quail birds (Sant-Ana *et al.*, 2005). The dose and time dependent experiment decreased the body weight gain in birds which is in accordance with our current study results (Vodella *et al.*, 1997). Body weight and organ weight is considered as reflected practical example of organ normal physiology. Pattern of physiology and growth of Organs showed unlike path reliant to the function they execute (Chen *et al.*, 2015). In the present study, liver and kidney weight exposure to the heavy metals (zinc & cadmium) were altered doubtless due to injuries, possibly the accumulation of residue of heavy metals, resulted the elevation serum biochemical (Pasupuleti *et al.*, 2012; Esmaeillou *et al.*, 2013).

The current study showed that the heavy metals are injurious to health at different level and exhibit significant toxicity in Pigeons. We found that the zinc is not toxic at low level but it shaped toxicity at high level, similarly cadmium produce toxicity even at low level. The body weight, relative weight of liver, kidney, and serum biochemical (ALAT, ASAT, ALP, Creatinine and Uric acid) pretentious to the Zinc and Cadmium.

Acknowledgment

We would like to thank the Director CSL (Centralized Science Laboratory) of University of Karachi for their kind corporation and support. We showed gratitude to Ibrahim Hussain (Ph.D. Scholar, Chemistry) for providing chemicals during experimental work. We are indebted to Sir Ahsan Ali (Research Scholar of Statistics) for statistical analysis and modeling.

Conflict of Interest

The author declares that they have no competing and conflicting interest.

REFERENCES

- Abdel-Khalek, A.A., M. Kadry., A. Hamed and M.A.Marie (2015). Ecotoxicological impacts of zinc metal in comparison to its nanoparticles in Nile tilapia; *Oreochromis niloticus*. *The Journal of Basic & Applied Zoology*, 72:113–125.
- Abdel-Tawwab, M., G.O. El-Sayed and S.H.H.H. Shady (2011). Acute toxicity of water-born zinc in Nile tilapia, *Oreochromis niloticus* (L.) fingerlings. In: *Proceedings of the Ninth International Symposium on Tilapia in Aquaculture, Shanghai Ocean Univ. China.*, 44–50.
- Abou-Kassem D.E., K.M. Mahrose and M. Alagawany (2016). The role of vitamin E or clay in growing Japanese quail fed diets polluted by cadmium at various levels. *Animal*, 10:508–19.
- ATSDR Agency for Toxic Substances and Disease Registry (2017). U.S Toxicological profile for Cadmium (Cd). Department of Health and Human Services, Public Health service, Center for disease control, Atlanta, GA, U.S.A.
- Al-Daraji, H.J. and M.H.M. Amen (2011). Effect of dietary zinc on certain blood traits of broiler breeder chickens. *International Journal Poultry Research*, 10(10):807-813.
- Artacho, P., M. Soto-Gamboa., C. Verdugo and R.F. Nespolo (2007). Blood biochemistry reveals malnutrition in black-necked swans (*Cygnus melanocoryphus*) living in a conservation priority area. *Comparative Biochemistry and Physiology Part A: Molecular & Integrative Physiology*, 146: 283–290.
- Bharavi, K., A.G. Reddy., G.S. Rao., A.R. Reddy., S.R. Rao (2010). Reversal of cadmium-induced oxidative stress in chicken by herbal adaptogens with *Aniasomnifera* and *Ocimum sanctum*. *Toxicoloint.*, 17:2–59.
- Bodar, C.W., M.E. Pronk and D.T. Sijm (2005). The European Union risk assessment on zinc and zinc compounds: The process and the facts. *Integr. Environ Assess Manag.*, 1:301–19.
- Chen, M. X., X. G. Li, J. X. Yang, C. Q. Gao., B. Wang., X. Q. Wang and H. C. Yan (2015). The growth of embryo and gene expression of nutrient transporters in the small intestine of the domestic pigeon (*Columba livia*). *J. Zhejiang Univ. Sci. B*. 16:511–23.
- Esmaeillou, M., M. Moharamnejad., R. Hasankhani., A.A. Tehrani and H. Maadi (2013). Toxicity of ZnO nanoparticles in healthy adult mice. *Environ Toxicol Pharmacol.*, 35(1):67–71.
- Fathi M., M. Haydari and T. Tanha (2016). Effects of zinc oxide nanoparticles on antioxidant status, serum enzymes activities, biochemical parameters and performance in broiler chickens. *Journal of Livestock Science and Technologies.*, 4(2):7-13.

- Fazilati, M. (2013). Investigation toxicity properties of zinc oxide nanoparticles on liver enzymes in male rat. *European Journal of Experimental Biology*, 3:97-10.
- Godshe, S., B. Bharucha and G. Padate (2012). Cornification and assessment of various environmental toxicants from feathers of black kite A preliminary study. *Int J Pharm BioSci.*, 3(4):465-474.
- Henderson, A.R. and D.W. Moss (2001). Enzymes Tietz Fundamentals of Clinical Chemistry, 5th ed., Burtis, C.A. & Ashwood, E.R. (W.B. Saunders eds. Philadelphia USA), 352.
- Jacobson-Kram, D. and K.A. Keller (2001). Toxicology testing handbook. Marcel Dekker, New York, NY.
- Jaishankar, M., T. Tseten., N. Anbalagan., B.B. Mathew and K.N. Beeregowda (2014). Toxicity, mechanism and health effects of some heavy metals. *Interdiscip Toxicol.*, 7(2): 60–72.
- Jarup, L. and A. Akesson (2009). Current status of cadmium as an environmental health problem. *Toxicol. Appl. Pharmacol.* 238: 201–208.
- Kant, V., M. Mehta., C. Varshneya and S. Chauhan (2011). Induction of oxidative stress by subacute oral exposure of cadmium sulphate in adult poultry. *Braz. J. Vet. Pathol.*, 4:117–21.
- Kar, I., S.K. Mukhopadhyay., A.K. Patra and S. Pradhan (2015). Metal concentrations and histopathological changes in goats (*Capra hircus*) reared near an industrial area of West Bengal, India. *Arch Environ Contam Toxicol.*, 69:32–43.
- Karimi M, M., M. J. Sani., A.Z. Mahmudabadi., A.J. Sani and S.R. Khatibi (2012). Effect of acute toxicity of cadmium in mice kidney cells. *Iranian J. Toxicol.*, 6(18):691–698.
- Kaur, N., and C. K. Dhanju (2013). Heavy metals concentration in excreta of free living wild birds as indicator of environmental contamination. *The Bioscan.*, 8 (3):1089-1093.
- Kibria, G. (2018). Risk and management of heavy metals; Environment and public health.
- Kim, S.G. and J.C. Kang (2004). Effect of dietary copper exposure on accumulation, growth and hematological parameters of the juvenile rockfish, *Sebastes schlegeli*. *Mar. Environ. Res.* 58: 65–82.
- Kori-Siakpere, O. and E.O. Ubogu (2008). Sub-lethal hematological effects of zinc on the freshwater fish, *Heteroclinus sp.* (Osteichthyes: Clariidae). *Afr. J. Biotechnol.*, 7: 2068-2073.
- Lane, E.A., Canty, M.J., More, S.J., (2015). Cadmium exposure and consequence for the health and productivity of farmed ruminants. *Res. Vet. Sci.*, 101: 132-139.
- Laura, M.P., L. Rink and H. Haase. (2010). The Essential Toxin: Impact of Zinc on Human Health. *Int. J. Environ. Res. Public Health.*, 7: 1342-1365.
- Maity, S., S. Roy., S. Chaudhury., and S. Bhattacharya (2008). Antioxidant responses of the earthworm *Lampitoma mauritii* exposed to Pb and Zn contaminated soil. *Environ. Pollut.*, 151:1–7.
- Mohajeri, G., M.A., Norouzian, M. Mohseni and A. Afzalzadeh (2014). Changes in blood metals, hematology and hepatic enzyme activities in lactating cows reared in the vicinity of a lead-zinc smelter. *Bull. Environ. Contam. Toxicol.*, 92(6):693–697.
- Morais, S., F.G. Costa and M.L. Pereira (2012). Heavy metals and human health, in Environmental health emerging issues and practice, (Oosthuizen J ed), *InTech.*, 227–246.
- Nagalakshmi, D., K. Sridhar and S. Parashuramulu (2015). Replacement of inorganic zinc with lower levels of organic zinc (zinc nicotinate) on performance, hematological and serum biochemical constituents, antioxidants status and immune responses in rats. *Veterinary World.*, 8(9):1156-1162.
- Newman, D.J. and C.P. Price. 2001. Nonprotein Nitrogen Metabolite. Tietz Fundamentals of Clinical Chemistry, 5th edition, Burtis, C.A & E.R. Ashwood. (W.B. Saunders eds. Philadelphia USA., 414.
- Newman, D.J. and C.P. Price. 1999. Renal function and Nitrogen Metabolite. In, Burtis Tietz Fundamentals of Clinical Chemistry, 3rd edition, Burtis, C.A & E.R. Ashwood. (W.B. Saunders eds. Philadelphia USA., 1204-70.
- Orlewick, M.S. and E. Vovchuk (2012). Alanine Aminotransferase [on line]. [Accessed on 14.11.2013].
- Pasupuleti, S., S. Alapati., S. Ganapathy., G. Anumolu., N.R. Pully and B.M. Prakhya (2012). Toxicity of zinc oxide nanoparticles through oral route. *Toxicol Ind. Health.*, 28(8):675–686.
- Persky, A.M., and G.A. Brazeau (2001). Clinical pharmacology of the dietary supplement creatine monohydrate. *Pharmacological Reviews.*, 53:161–176.
- Piao, F., K. Yokoyama., N. Ma and T. Yamauchi (2003). Subacute toxic effects of zinc on various tissues and organs of rats. *Toxicol. Lett.*, 145: 28–35.
- Raza, A., M. Ayaz and S. Rafi (2017). Bioaccumulation and effects of heavy metals in avian fauna of Asian scavenging species; A Review. *Annals of Life Sciences.* 1(1): 9–13
- Renugadevi, J. and S.M. Prabu (2010). Cadmium-induced hepatotoxicity in rats and the protective effect of naringenin. *Exp. Toxicol. Pathol.*, 62: 171-181.
- Rikans, L.E. and T. Yamano (2000). Mechanisms of cadmium-mediated acute hepatotoxicity. *J. Biochem. Mol. Toxicol.*, 14(2):110–117.

- Sant-Ana, M.G., R. Moraes and M.M. Bernardi (2005). Toxicity of cadmium in Japanese quail: valuation of body weight, hepatic and renal function, and cellular immune response. *Environ. Res.*, 99:273–7.
- Sarkar, A., G. Ravindran and V. Krishnamurthy (2013). A brief review on the effect of cadmium toxicity: from cellular to organ level. *Int. J. Biotech. Res.*, 3:17-36.
- Scherwin, J.E. 2003. Liver Function. *Clinical Chemistry: Theory, Analysis, Correlation*, 4th ed., Mosby, Inc, eds, St Louis USA, 492.
- Sun, B. and M. Xing (2016). Evaluated the twenty-six elements in the pectoral muscle of As-treated chicken by inductively coupled plasma mass spectrometry. *Biol. Trace Elem. Res.*, 169(2):359–364.
- Uyanik, F., M. Eren., A. Atasever., G.T. Oku and A.H. Kolsuz. (2001). Changes in some biochemical parameters and organs of broiler exposed to cadmium and effects of zing on cadmium induced alteration. *Israel Journal of Veterinary Medicine.*, 56(4):128-134.
- Van-Dyk, J.C., G.M. Pieterse and J.H.J. Van-Vuren (2007). Histological changes in the liver of *Oreochromis mossambicus* (Cichlidae) after exposure to cadmium and zinc. *Ecotoxicol. Environ. Safety.*, 66(3): 432-440.
- Ventura, L.M.B., V.L. Mateus., A.C.S.L. De-Almeida., K.B. Wanderley., F.T., Taira, T.D. Saint-Pierre and A. Gioda (2017). Chemical composition of fine particles (PM_{2.5}): Water-soluble organic fraction and trace metals. *Air Quality, Atmosphere and Health.*, 10:845-852.
- Vodola, J.K., S.D. Lenz., J.A. Renden., W.H. McElhenney and B.W. Kemppainen (1997). Drinking water contaminants (arsenic, cadmium, lead, benzene, and trichloroethylene). 2. Effects on reproductive performance, egg quality, and embryo toxicity in broiler breeders. *Poult. Sci.*, 76:1493–500.
- Wu, R.S., C.A. Pollino., D.W. Au., D.W. Zheng., B. Yuen., P.K. Lam (2003). Evaluation of biomarkers of exposure and effect in juvenile areolated grouper (*Epinephelus areolatus*) on food-borne exposure to benzo-a-pyrene. *Environ. Toxicol. Chem.*, 22: 68–73.
- Younis, E.M., A.A. Abdel-Warith and N.A. Al-Asgah (2012). Hematological and enzymatic responses of Nile tilapia *Oreochromis niloticus* during short and long term sub-lethal exposure to zinc. *Afr. J. Biotechnol.*, 11: 4442–4446.
- Zhuang, Y., P. Liu., C.Y. Zhang., G.L. Hu and H.B. Cao (2016). Effect of cadmium on the concentration of Ceruloplasmin and its mRNA expression in goats under molybdenum stress. *Pak. Vet. J.* 36:209–13.

(Accepted for publication March 2019)